

EP-2078: PROSPECT: Phase 2 rescanning of seromas in patients to evaluate CTV reduction in breast cancer

SMITH, G., ROBSON, P. and PROBST, Heidi <<http://orcid.org/0000-0003-0035-1946>>

Available from Sheffield Hallam University Research Archive (SHURA) at:

<https://shura.shu.ac.uk/26592/>

This document is the author deposited or published version.

Citation:

SMITH, G., ROBSON, P. and PROBST, Heidi (2016). EP-2078: PROSPECT: Phase 2 rescanning of seromas in patients to evaluate CTV reduction in breast cancer. *Breast Cancer Research and Treatment*, 119 (Supp1), S980. [Article]

Copyright and re-use policy

See <http://shura.shu.ac.uk/information.html>

cumulated medical data are needed to reduce steps by steps the uncertainties in the assumptions used in the present models.

EP-2078

PROSPECT: Phase 2 rescanning of seromas in patients to evaluate CTV reduction in breast cancer

G. Smith¹, P. Robson², H. Probst³

¹The Clatterbridge Cancer Centre - Wirral NHS Foundation Trust, Radiotherapy Planning, Bebington- Wirral, United Kingdom

²The Clatterbridge Cancer Centre - Wirral NHS Foundation Trust, Radiotherapy, Bebington- Wirral, United Kingdom

³Sheffield Hallam University, Faculty of Health and Wellbeing, Sheffield, United Kingdom

Purpose or Objective: A single centre feasibility study to assess the reduction in sequential boost volume treated by rescanning patients during their final week of whole breast radiotherapy.

Material and Methods: Patients requiring a sequential boost treatment who had a tumour bed seroma greater than 1cm on the initial radiotherapy planning (RTP) CT scan were considered for entry into the study.

Thirty patients were sequentially recruited at the planning stage if they met this inclusion criteria. Patients were consented for entry into the trial and a second RTP CT scan (RTP 2) was conducted in their final week of whole breast radiotherapy. RTP 2 scan was used to determine the volume treated for their sequential boost.

Both scans had the CTV outlined by the chief investigator and the CTV volume changes were annotated.

Results: 83% of patients had a substantial reduction in CTV (>25%) in RTP 2 compared to RTP 1. The mean CTV reduction overall was 41.9% with a median reduction 42.5%. The mean time between scans was 27 days; median time 29 days. Mean time from start of whole breast radiotherapy treatment to RTP 2 was 14 days.

Conclusion: This study shows that rescanning breast patients during the final week of whole breast radiotherapy leads to a significant decrease in treated boost volume in the majority of patients.

EP-2079

IMRT vs. dynamic conformal arc radiation therapy for stereotactic spinal radiotherapy

V. Santos¹

¹Mercurius Health- SA, Centro Oncológico Dra. Natália Chaves - Unidade de Radioterapia de Lisboa - Quadrantes - Joaquim Chaves Saúde, Lisboa, Portugal

Purpose or Objective: Patients with spinal tumors have better outcomes with increased dose prescription. Due to the complex geometry of the treatment site and to the close proximity of the spinal cord, dose escalation is only possible with advanced techniques. This case study aims to determine if intensity-modulated radiation therapy (IMRT) could be a better option than dynamic conformal arc radiation therapy (DCA) for stereotactic spinal treatments.

Material and Methods: Six patients previously treated with DCA were re-planned with IMRT. The same patient-specific criteria were followed in the new IMRT plan. Plan quality was compared by analyzing the dose-volume histogram (DVH) for the planning target volume (PTV) and for the spinal cord (SC). The conformity index (CI) and the monitor units (MU) number were also compared.

Results: Both techniques provided adequate PTV coverage and SC sparing. Results favored IMRT in most of the analyzed PTV parameters: Dmax, D95, V95 and V100. DCA showed better results in PTV Dmin and D99 and had advantageous lower MU number. SC had superior dose sparing with IMRT plans. The CI was also improved by the IMRT technique.

Conclusion: In general, IMRT plans proved to be a better planning solution, although with a significant higher number of MUs. IMRT treatments must be performed with higher accurate imaging guidance systems.

EP-2080

Redefining the possible: planning multiple complex head lesions using non-coplanar VMAT arcs

V. Guy¹, R. Sims¹, A. Falkov¹

¹Auckland Radiation Oncology, Auckland Radiation Oncology, Auckland, New Zealand

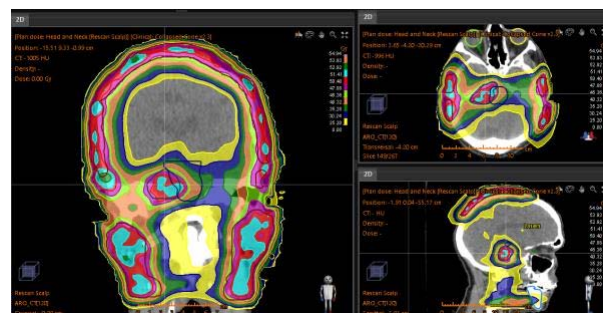
Purpose or Objective: To demonstrate the ability to include multiple lesions over the scalp, face and brain using non-coplanar VMAT beams and a single isocentre
73 yo man referred for post-op RT to multiple scalp lesions, including bilateral spread to periauricular and parotid nodes. Diagnostic work up also showed an incidental right sided meningioma that was indicated for possible concurrent treatment.

Material and Methods: The patient was scanned in a Klarity shell, on a Philips Big Bore CT. The dataset was imported into the TPS and diagnostic T1 and T2 MRI's were fused for assisting in contouring.

The scalp and bilateral periauricular and parotid regions were contoured as a single CTV and a 0.3cm PTV margin was added. The meningioma was contoured separately, also with a 0.3cm PTV margin applied.

50.4Gy in 28 fractions was prescribed and the plan was generated in RayStation (v4.0.3) on an Elekta Synergy machine with 4° gantry spacing and a maximum delivery time of 90 seconds per beam. Two full transverse VMAT arcs were used with a partial sagittal arc added (floor at 270°). Isocentre placement was key due to potential collision risks.

Results: Exceptional conformality was achieved. The introduction of the sagittal arc created a ring of dose around the skull providing excellent brain sparing as shown in Figure 1.



QA was performed using a 3D diode array with 99.6% pass rate at 3%/3mm criterion (6/1605 failed diodes). Absolute dose measurements were done using a pinpoint ionisation chamber inside both the scalp and meningioma PTVs indicating agreement with the TPS to within $\pm 3.0\%$.

XVI imaging was performed on fractions 1 to 3, then weekly, using grey scale match. Bony anatomy matched with $<1^\circ$ rotation. Treatment delivery averaged at 10 minutes making this beam arrangement extremely efficient to treat.

Treatment was tolerated very well. Some changes to taste, dysphagia and mild to moderate xerostomia developed during the later stages of treatment. This was managed with general analgesia. There was no evidence of recurrence at three month follow up and the RO is now awaiting further diagnostic MRI's.

Conclusion: Combining traditional transverse arcs with a partial non-coplanar arc is a safe and efficient technique to treat multiple head and neck volumes and provides exceptional sparing and dosimetric accuracy. The sagittal arc was integral to this conformal distribution over these complex PTV's.