

Evaluation of the non-contact 3D laser in the measurement of breast volume.

LAW, Siobhan, CHOPPIN, Simon <<http://orcid.org/0000-0003-2111-7710>> and ROSBOTTOM, Keeley

Available from Sheffield Hallam University Research Archive (SHURA) at:

<http://shura.shu.ac.uk/24975/>

This document is the author deposited version. You are advised to consult the publisher's version if you wish to cite from it.

Published version


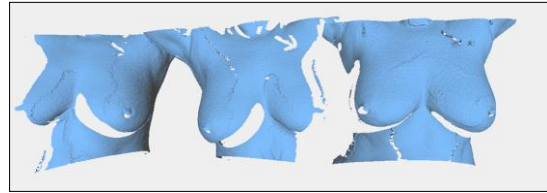
LAW, Siobhan, CHOPPIN, Simon and ROSBOTTOM, Keeley (2016). Evaluation of the non-contact 3D laser in the measurement of breast volume. In: Association of Breast Surgery Conference, Manchester, UK, 16-17 May 2016. (Unpublished)

Copyright and re-use policy

See <http://shura.shu.ac.uk/information.html>

Evaluation of the non contact 3D laser in the measurement of breast volume.

Laws, Choppin, Rosbottom*, Peiris, Rainsbury
Royal Hampshire County Hospital, Winchester. SO22 5DG.
Faculty of Health and Wellbeing, Sheffield Hallam University, Sheffield, S10 2BP



Introduction

A 3D laser surface scanner can obtain a highly accurate topographical map of the breast rapidly and is non-invasive. There is a need to study objectively the long term cosmetic outcome of all types of breast cancer treatment and its relation to patient quality of life. With objective data, surgical techniques can be refined and patient counseling improved.

Methods

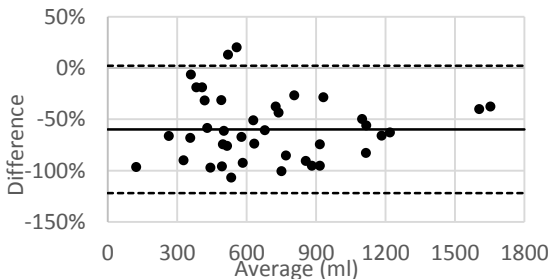
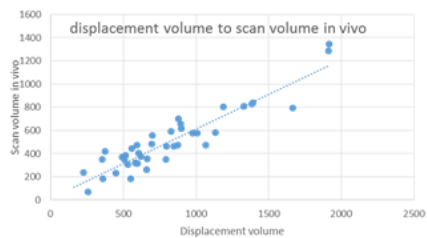
In clinical trial 11/WM/0100, 58 patients consented to preoperative 3D laser scans with Vivid Vi9 or Vi 910 (Minolta). Preoperative volume calculations were compared with mammographically derived volumes, breast weight, displacement volume and removed breast scan volume. Mammographic breast volumes calculated using volume of cone. Scans were processed using Meshlab (<http://meshlab.sourceforge.net/>). 3 separate scans of the participant are aligned into a single view, holes are healed and a complete surface formed using Poisson reconstruction. The boundary of the breast is manually identified and used to separate the breast from the torso, forming the rear wall of the breast which is combined with the breast surface to form a closed volume.

Discussion

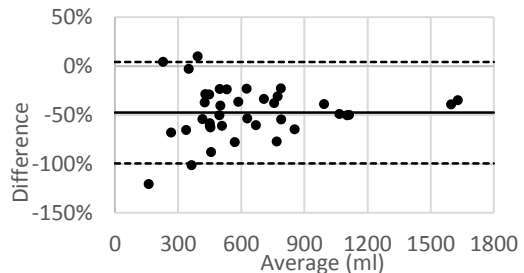
3D laser scans are easily acquired but at present require considerable post acquisition manipulation. The calculated 3D laser breast volume is consistently smaller than standard volume estimates. Further work is required to understand this discrepancy.

Conclusion

There is great potential for the 3D laser to objectively measure breast volume where other methods are inappropriate eg post radiotherapy or reconstruction.



Bland-Altman, Scan vs Displacement



Bland-Altman, Scan vs Mammogram