

Arterial spin labelling shows functional depression of non-lesion tissue in chronic Wernicke's Aphasia

ROBSON, H, SPECHT, K, BEAUMONT, H, PARKES, L.M., SAGE, K
<<http://orcid.org/0000-0002-7365-5177>>, LAMBON RALPH, M.A. and ZAHN, R

Available from Sheffield Hallam University Research Archive (SHURA) at:

<http://shura.shu.ac.uk/13948/>

This document is the author deposited version. You are advised to consult the publisher's version if you wish to cite from it.

Published version

ROBSON, H, SPECHT, K, BEAUMONT, H, PARKES, L.M., SAGE, K, LAMBON RALPH, M.A. and ZAHN, R (2017). Arterial spin labelling shows functional depression of non-lesion tissue in chronic Wernicke's Aphasia. *Cortex*, 92, 249-260.

Copyright and re-use policy

See <http://shura.shu.ac.uk/information.html>

Arterial Spin Labelling Shows Functional Depression of Non-Lesion Tissue in Chronic
Wernicke's Aphasia

AUTHOR: *ROBSON, Holly¹, SPECHT, Karsten², BEAUMONT, Helen³, PARKES, Laura M.⁴, SAGE, Karen⁵, LAMBON RALPH, Matthew A.⁶, ZAHN Roland⁷.

1: Department of Psychology and Clinical Language Sciences, University of Reading, UK

2: Department of Biological and Medical Psychology, University of Bergen, Norway, and
Department of Clinical Engineering, Haukeland University Hospital, Bergen, Norway

3: Department of Neurology, Washington University

4: Centre for Imaging Science, Institute of Population Health, University of Manchester, UK

5: Centre for Health and Social Care Research, Faculty of Health and Wellbeing, Sheffield
Hallam University, Sheffield, UK

6: Neuroscience and Aphasia Research Unit, School Psychological Sciences, University of
Manchester, UK

7: Department of Psychological Medicine, Kings College London, UK

* Corresponding author: Psychology and Clinical Language Sciences, University of Reading, Earley Gate, Reading, RG6 6AL, UK. h.v.robson@reading.ac.uk

Abstract:

Behavioural impairment post-stroke is a consequence of structural damage and altered functional network dynamics. Hypoperfusion of intact neural tissue is frequently observed in acute stroke, indicating reduced functional capacity of regions outside the lesion. However, cerebral blood flow is rarely investigated in *chronic* stroke. This study investigated cerebral blood flow in individuals with chronic Wernicke's aphasia and examined the relationship between lesion, cerebral blood flow and neuropsychological impairment.

Arterial spin labelling cerebral blood flow imaging and structural MRIs were collected in 12 individuals with chronic Wernicke's aphasia and 13 age-matched control participants. Joint independent component analysis (jICA) investigated the relationship between structural lesion and hypoperfusion. Partial correlations explored the relationship between lesion, hypoperfusion and language measures.

Joint ICA revealed significant differences between the control and WA groups reflecting a large area of structural lesion in the left posterior hemisphere and an associated area of hypoperfusion extending into grey matter surrounding the lesion. Small regions of remote cortical hypoperfusion were observed, ipsilateral and contralateral to the lesion. Significant correlations were observed between the neuropsychological measures (naming, repetition, reading and semantic association) and the jICA component of interest in the WA group. Additional ROI analyses found a relationship between perfusion surrounding the core lesion and the same neuropsychological measures.

This study found that core language impairments in chronic Wernicke's aphasia are associated with a combination of structural lesion and abnormal perfusion in non-lesioned tissue. This indicates that post-stroke impairments are due to a wider disruption of neural function than observable on structural T1w MRI.

1.1 Introduction:

The impact of a neural lesion extends beyond the site at which the lesion occurs (Feeney and Baron, 1986). Cognitive functions are supported through the integration of highly interconnected cortical and subcortical regions and, therefore, lesions to isolated network components can cause widespread dysfunction. As such, accounting for behavioural profile/impairment after stroke requires both the site of lesion as well as the functional status of remaining network components to be considered. In this study we investigate the relationship between stroke damage and the functional potential of wider neural regions in a group of individuals with chronic Wernicke's aphasia by exploring associations between structural lesion and residual cerebral blood flow. We further examine the relationship between these imaging profiles and neuropsychological impairment.

Within the first hours of an acute stroke, patients show regions of hypoperfusion, which often extend beyond the limits of the observable structural lesion (Neumann-Haefelin, et al., 1999). This hypoperfusion can occur in the form of ischaemic penumbra, surrounding the area of core infarction (Croquelois, et al., 2003), or remote from the area of infarction, termed focal diaschisis (Carrera and Tononi, 2014; Feeney and Baron, 1986). Diaschisis most commonly occurs between cortical and subcortical regions; lesions to subcortical areas lead to cortical dysfunction and cortical lesions can lead to subcortical alterations (Bowler, et al., 1995; Feeney and Baron, 1986; Hillis, et al., 2002; Price, et al., 2001). Remote cortico-cortico hypoperfusion/hypometabolism is only rarely reported but is often transcallosal (Andrews, 1991; Carrera and Tononi, 2014). Cerebral blood flow supplies oxygen and glucose required for neuronal function and is associated with neuronal activity through neurovascular coupling

(Girouard and Iadecola, 2006). Therefore, regional hypoperfusion indirectly indicates reduced functional capacity of associated neural tissue. These hypoperfusion patterns in the acute phase indicate that behavioural impairment emerges, partially, as a consequence of infarcted tissue and functional depression of intact tissue.

Wernicke's aphasia (WA) is an acquired language impairment which occurs at both the acute and chronic phases following lesions to the left posterior temporal lobe and inferior parietal lobe (Ogar, et al., 2011; Robson, et al., 2014b). WA is characterised by severely impaired language comprehension and repetition in the context of fluent speech and relatively well preserved mobility. This impairment profile is underpinned by a spectrum of neuropsychological impairments including verbal short term memory (Robson, et al., 2012), acoustic (Robson, et al., 2013), phonological (Baker, et al., 1981) and semantic (Cohen, et al., 1980; De Renzi, et al., 1972) processing impairments. The WA comprehension impairment at the acute phase has been associated with hypoperfusion of the left posterior superior temporal and inferior parietal regions (Hillis, et al., 2001; Jodzio, et al., 2003) with re-perfusion of these regions leading to improvements of language comprehension (Hillis, et al., 2001). At the chronic stage, *structural* imaging investigations have found similar relationships between structural lesion and language comprehension impairments of the WA type, specifically following lesions to mid-posterior middle temporal areas (Dronkers, et al., 2004).

Hypoperfusion investigations of WA at the chronic stage have not matched those undertaken at the acute phase. This may be because diaschisis and penumbral regions are frequently observed to re-perfuse or evolve to lesion (Binkofski, et al., 1996; Butcher, et al., 2005; Neumann-Haefelin, et al., 1999; Seitz, et al., 1999; Toni, et al., 1997). There is, however,

some limited evidence to suggest that hypoperfusion of structurally intact tissue can occur in chronic stroke (Barber, et al., 2001; Brumm, et al., 2010; Raynaud, et al., 1987) and this has implications for understanding the mechanisms of recovery and source of impairments post-stroke.

In this study we investigated whether hypoperfusion of intact tissue, outside the lesion site, could be identified in chronic WA and explored the relationship between hypoperfusion and a range of neuropsychological symptoms observed in WA. Arterial spin labelling, a non-invasive measure of cerebral blood flow, and structural T₁-weighted MRI data were collected in a group of 12 individuals with chronic WA. Statistical analysis used joint independent component analysis (ICA). Joint ICA is a multimodal multivariate analysis which combines multiple imaging modalities, enabling patterns across modalities to be detected (Abel, et al., 2015; Calhoun, et al., 2009). This analysis enabled the identification of regions of hypoperfusion statistically related to areas of structural lesion. Correlational analyses then investigated the relationship between cerebral blood flow and lesion distribution and neuropsychological profile.

2.1 Materials and Methods:

Ethical approval was provided by the North-West NRES committee, UK. Twelve individuals with Wernicke's aphasia (WA, two female) were recruited from local National Health Service Speech Therapy services. Thirteen age-matched controls (two female) with no neurological history were recruited from a panel of research volunteers, Table I.

2.1.1 Neuropsychological Assessment:

All stroke participants were in the chronic phase of their acquired aphasia (at least 7 months post onset, Table 1) following cerebral infarction. No clinical information was available regarding cardiovascular risk factors or stenosis. No participant with WA presented with pre-stroke decline and all individuals had displayed a degree of post-stroke recovery. Participants were screened with the Boston Diagnostic Aphasia Examination – Short Form (Goodglass, et al., 2001) which confirmed diagnosis of WA, Table I. The majority of individuals presented with severe single word auditory comprehension and repetition impairments. The presence of jargon in spontaneous speech was not a WA inclusion criterion for the current study. However, five of the twelve participants did present with jargon speech (DL, DM, DMC, DR & LS), these were the more severely impaired individuals, see Table II. The remaining participants produced phonological non-word errors during neuropsychological testing and in discourse; however, spontaneous speech was not affected to a sufficient extent to be considered jargon. Further neuropsychological testing examined cognitive-semantic skills and phonological skills. Non-verbal semantic performance was assessed with the Pyramids and Palm Trees semantic association test (three-picture version) (Howard and Patterson, 1992). Additionally, the Raven’s Coloured Progressive Matrices (Raven, 1962), a test of non-verbal reasoning was administered. Phonological skills were examined with 80-item reading and repetition tests from the PALPA battery (Kay, et al., 1992). A naming assessment from the Cambridge Semantic Battery (Bozeat, et al., 2000) was included and which requires both semantic and phonological processing. Neuropsychological assessment results are detailed in Table II and in the results section. Overall, all individuals presented within the spectrum of WA but with a range of impairment severity on comprehension, production and semantic tasks.

BDAE Percentile									
WA	Age	Sex	TPO	Comprehension	Repetition	Fluency	Control	Age	Sex
CH	77	M	17m	40	45	100	AM	58	M
CW	70	M	3y	45	40	100	BH	67	M
DL	73	M	9m	3	<1	63	BR	76	M
DM	75	M	16m	13	<1	57	DW	72	M
DMC	67	M	10m	3	<1	47	EC	78	F
DR	76	M	7m	2	<1	47	GP	78	M
EL	61	M	15m	14	10	75	HE	76	M
LB	80	F	7y	5	5	68	KE	52	F
LS	66	M	10m	5	25	70	KW	69	M
MC	73	F	13m	10	10	83	ML	66	M
NM	59	M	11m	17	10	100	NJ	78	M
RD	87	M	17m	10	5	80	PD	60	M
							TT	61	M

Table I: Demographic information presented for WA and control participants. BDAE = Boston Diagnostic Aphasia Examination – Short Form (Goodglass *et al.*, 2001). BDAE criteria for WA is comprehension < 47th centile, repetition < 60th centile and fluency > 45th centile. TPO = time post onset

2.1.2 WA Lesion and Cerebral Blood Flow Profiles:

Automated lesion delineation was performed on T1-weighted MRI scans using the Fuzzy Clustering method (Seghier, et al., 2008). Lesions extended over the middle cerebral artery territory with peak overlap in the left mid-posterior superior and middle temporal lobe and inferior parietal lobe. Over the group, lesions extended outside these core regions into occipital, middle and anterior temporal, insular and inferior frontal areas, see Fig 1 A. The lesion pattern was mirrored by significant cerebral blood flow (CBF) reductions over the left hemisphere, see Fig. 1 B. The average CBF to the left and right hemispheres was extracted from the pre-processed smoothed CBF maps in both the WA and control group using the MarsBar software (Brett, et al., 2002). The WA group displayed an average CBF of 29.3 ml/100ml/min, sd. 7.1 ml/100ml/min in the left hemisphere and an average of 39.1 ml/100ml/min, sd. 6.2 ml/100ml/min in the right hemisphere. The control group displayed an average CBF of 37.8 ml/100ml/min, sd. 7.0 ml/100ml/min in the left hemisphere and an average of 39.8 ml/100ml/min, sd. 6.5 ml/100ml/min in the right hemisphere. A 2x2 ANOVA exploring the effects of group and hemisphere on CBF found a significant main effect of group ($F_{(1,44)} = 5.1, p = 0.029$) due to significantly reduced CBF in the WA group compared to the controls, a main effect of hemisphere ($F_{(1,44)} = 9.0, p = 0.004$) due to less CBF to the left hemisphere in both the WA and the control group and a borderline hemisphere x group interaction ($F_{(1,44)} = 3.5, p = 0.067$) caused by a greater hemisphere CBF difference (left<right) in the WA than the control group. In addition, we extracted the average CBF from both groups from left hemisphere regions which were not affected by lesion in any WA participant (WA: ave. CBF 31.5 ml/100ml/min, sd. 7.5 ml/100ml/min; Cont. ave CBF 37.0 ml/100ml/min, sd. 6.8 ml/100ml/min); despite not including any area of lesion, the difference between the groups displayed a borderline significant difference ($t_{(23)} = 1.9, p=0.067$).

	Cognitive-Semantic Tasks		Phonological Tasks		
	PPT	RCPM	Reading	Repetition	Naming
WA	max. 52	max. 33	max. 80	max. 80	max. 64
CH	50	31	<i>19</i>	<i>21</i>	<i>18</i>
CW	52	29	<i>44</i>	<i>39</i>	<i>41</i>
DL	32	22	<i>14</i>	<i>1</i>	<i>2</i>
DM	40	24	<i>1</i>	<i>0</i>	<i>0</i>
DMC	39	23	<i>1</i>	<i>0</i>	<i>0</i>
DR	33	10	<i>0</i>	<i>1</i>	<i>3</i>
EL	36	27	<i>27</i>	<i>14</i>	<i>24</i>
LB	42	21	<i>14</i>	<i>7</i>	<i>12</i>
LS	34	21	<i>0</i>	<i>5</i>	<i>1</i>
MC	47	30	<i>21</i>	<i>16</i>	<i>20</i>
NM	52	31	<i>28</i>	<i>43</i>	<i>28</i>
RD	52	22	<i>4</i>	<i>7</i>	<i>8</i>

Table II: Neuropsychological Assessment Results. PPT = Three picture version of the Pyramids and Palm Trees Test (Howard and Patterson, 1992), a visual semantic association task. RCPM = Raven’s Coloured Progressive Matrices (Raven, 1962), a non-verbal reasoning task. Reading and repetition tasks are taken from the Psycholinguistic Assessment of Language Processing in Aphasia (PALPA: Kay *et al.*, 1992), Naming assessment was taken from the Cambridge Semantic Battery (Bozeat *et al.*, 2000). *Italicised* result indicates participant outside normal limits. No normal cut-off data are available for RCPM.

2.2 Neuroimaging:

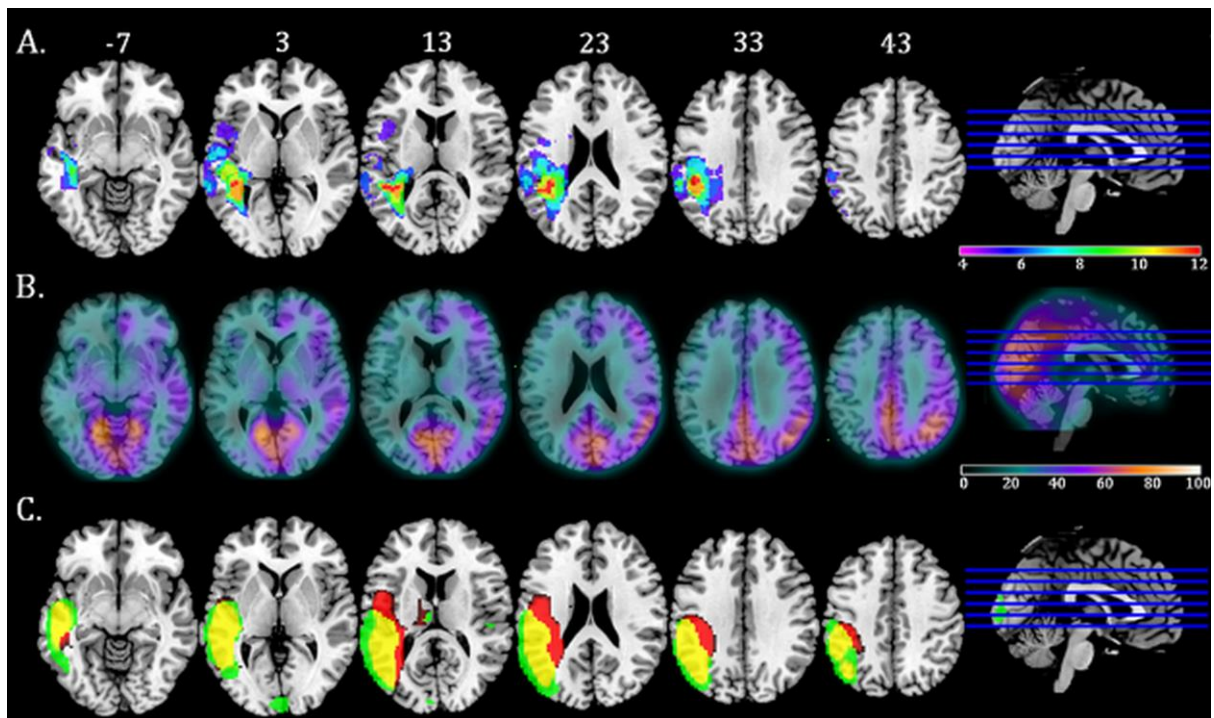
Structural T1- weighted images and arterial spin labelling (ASL) images were collected on a 3T Philips Achieva Scanner with an eight-element SENSE head coil. T1-weighted imaging used a 3D inversion recovery sequence to produce a 256 x 256 matrix of 128 transverse slices of 1mm³ voxels. A multi-timepoint ASL sequence was used with STAR labelling (Edelman, et al., 1994), gradient echo EPI readout and the following scan parameters: label thickness 150mm; label gap 10mm; TE 21ms; TR 3000ms; 4 delay times of 800, 1200, 1600, 2000ms from label to start of readout; FOV 224 x 224mm; matrix size 64 x 64; 20 slices of 5mm thickness with 1mm gap. Voxel size 3.5 x 3.5 x 6.0mm³; 20 control/label pairs. Vascular crushing was enabled. An additional calibration scan with TR 10000ms, no label, was taken to allow quantification. CBF and arterial arrival time (AAT) were calculated from the four time points. AAT is not of central interest in the study, but it is important to correct CBF estimates for regional alterations in AAT that are known to occur in stroke (MacIntosh, et al., 2010).

2.2.1 Pre-processing:

T1-weighted and ASL CBF images were pre-processed with the SPM8 software (<http://www.fil.ion.ucl.ac.uk/spm/>) and Matlab2013a. T1-weighted images were co-registered and normalised to the SPM T1-weighted template, no lesion masking was used following the normalisation procedure detailed in Crinion et al. (2007). After normalisation, images were segmented into grey matter (GM), white matter (WM) and cerebrospinal fluid (CSF) maps. This segmentation procedure classifies areas of lesion as CSF, hereafter described as lesion maps. The ASL control/label images were aligned to the first image using the SPM “Align

function". Cerebral blood flow (CBF) maps were calculated from the mean ASL subtraction images using in-house software and the single-blood-compartment model described by Parkes et al (2004). A global blood equilibrium magnetisation value was calculated from the calibration scan using voxels within a head mask derived from the T1-weighted image. The relaxation time of blood was fixed at 1600ms (Stanisz, et al., 2005); the labelling efficiency at 0.9; the blood-brain partition coefficient at 0.9 (Roberts, et al., 1996) and the bolus width at 1100ms. The labelling efficiency and bolus width were taken from earlier unpublished studies using this sequence. Two-parameter fits for CBF were performed on a voxel-wise basis. If the fitted value for CBF was negative, it was set to zero; if greater than 250 ml/100ml/min, it was set to 250 ml/100ml/min. CBF maps were co-registered and normalised to the SPM8 EPI template. To account for differing volumes of different tissue types in the large ASL voxels, we carried out a partial volume correction on the CBF images. The partial volume correction calculation was carried out for each voxel independently. The CBF measured within the voxel was divided by the sum of probabilities of GM and WM within the voxel (i.e. total tissue), taken from the co-registered segmented T1w image. This correction factor was applied if GM probability + WM probability >0.1, as otherwise it can give an unacceptably large value for CBF. Finally, both the lesion and partial volume corrected CBF maps were smoothed with a 12mm full-width half-maximum Gaussian filter. All the normalised and smoothed images were inspected visually to confirm that the pre-processing procedure had not resulted in image distortion.

Figure 1: Lesion Overlap Map, CBF map and jICA Results for Component Six.



Panel A: Lesion overlap map derived using the fuzzy clustering method (Seghier, et al., 2008). Individual participants' lesions were overlaid onto an MNI template brain using the MRIcron software. Map displays voxels in which lesion overlap occurred in a minimum of a third of the WA group. Axial slices are presented with MNI Z coordinate.

Panel B: Cerebral Blood Flow map displaying the average CBF (ml/100ml/min) in the WA group.

Panel C: jICA result displaying component six. Map displays regions where presence of lesion (red) correlated with reduction in CBF (green). Overlapping areas of lesion and hypoperfusion are displayed in yellow.

2.2.2 Joint Independent Component Analysis:

Independent component analysis (ICA) is a multivariate statistical method which enables the separation and identification of sources underlying complex observable data (Stone, 2005). These sources, or components, are statistically independent and when linearly combined produce the best fit representation of the observable data. When applied to neuroimaging, ICA is able to extract the hidden spatiotemporal components within the data, thought to correspond to networks of functionally or structurally connected regions. Joint ICA (jICA) advances this procedure by allowing multiple modalities of data over multiple groups to be considered simultaneously (Calhoun, et al., 2009). This allows the shared information between different modalities to be examined (Rachakonda, et al., 2012). Components extracted from a jICA indicate modality specific spatial patterns that carry similar covariance between participants across the modalities, i.e. where information in one modality correlates with information in another modality (Abel, et al., 2015; Guo, et al., 2012; Specht, et al., 2009). For each component each participant has an associated component mixing coefficient, and group comparisons can be made by linear inference statistics on these coefficients.

Joint ICA was employed in the current study in order to identify spatial patterns of CBF related to spatial patterns of lesion and where significant differences in these patterns occur between stroke and control groups. Joint ICA analysis was implemented using the Matlab Fusion ICA Toolbox (FIT; for further methodological details see: <http://icatb.sourceforge.net>). Images from the two imaging modalities, CBF and lesion, were entered into the analysis for both the Wernicke's aphasia and control groups alongside binary masks created from an average of the control images GM and WM maps. The analysis estimated and subsequently derived seven z-scaled components using the INFOMAX algorithm. For each component a two-tailed t-test was performed to compare

each component's mixing matrix coefficients between the groups. Components of interest were those with a significant group difference of $p < 0.05$.

3.1 Results:

3.1.1: Neuropsychological Profile:

Participants with Wernicke's aphasia (WA) displayed consistent and severe impairments on neuropsychological tasks involving phonological processing: single word reading, single word repetition and picture naming, Table II. On these tasks the error rate ranged from almost 100% in the more severely impaired participants (DM, DMC, DR) to approximately 45% in the least severely impaired participant (CH). All individuals displayed a large proportion of phonological errors with semantic, circumlocution and no response errors occurring less frequently. Two thirds of the WA participants displayed impairments in the visual semantic association task (three picture version of the Pyramids and Palm Trees test) and these individuals also displayed lower scores on non-verbal reasoning (Raven's Colour Progressive Matrices). These data are consistent with previous reports of the neuropsychological profile in Wernicke's aphasia (e.g. Ogar, et al., 2011) and confirm a consistent contribution of phonological processing impairment with an additional contribution of semantic processing disruption in a large proportion of the population (Robson, et al., 2012)¹. This neuropsychological profile is consistent with the lesion distribution, Figure 1, in which core lesion overlap occurs in auditory-phonological processing regions of the superior temporal and supramarginal gyri with less consistent but still high overlap in surrounding semantic processing regions such as the angular and middle temporal gyri.

¹ Note that 4 WA participants in the current study also participated in Robson et al., 2012 which may artificially enhance the consistency between these studies.

3.1.2 Joint ICA:

One of the seven jICA components extracted (component 6) was found to have significantly different mixing coefficients between the WA and control groups. Fig. 2 displays component 6 loading parameters for participants in the WA and control groups.

Joint ICA results for component 6 are displayed in Fig.1C. Component 6 was associated with a large area of lesion in the left posterior middle-superior temporal lobe, inferior parietal lobe and superior occipital lobe. This lesion pattern was commensurate with the core lesion, i.e. the areas of greatest lesion overlap in the WA group, Fig. 1A. The component captured lesion affecting the WM adjacent to the posterior lateral ventricle extending medially into the lateral dorsal nucleus region of the thalamus and laterally to impact neighbouring GM.

As expected, this pattern of lesion was associated with hypoperfusion in overlapping areas. However, lesion distribution showed greater medial involvement, whereas hypoperfusion was observed in a wider area of GM lateral to and surrounding the core area of lesion. Outside the immediate lesion area two regions of hypoperfusion were observed: (1) A small cluster of voxels in the right middle superior temporal gyrus, anterior to the auditory core and adjacent to the posterior insula and (2) part of the mid lateral cuneus of the left occipital lobe.

Six further jICA components were extracted over which no significant group difference occurred. These components identified regions of lesion associated with only one or two members of the WA group, therefore not reaching group level significance, e.g. frontal lobe

lesion extension, as well as components associated with members of both group such as patterns of cerebral blood flow overlapping with default mode network regions including the posterior cingulate cortex and medial frontal lobe.

Figure 2: Component Six Mixing Matrix Loading

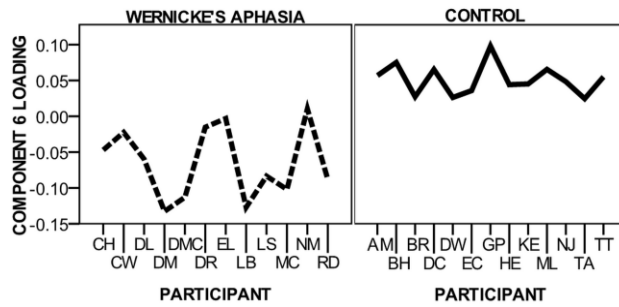


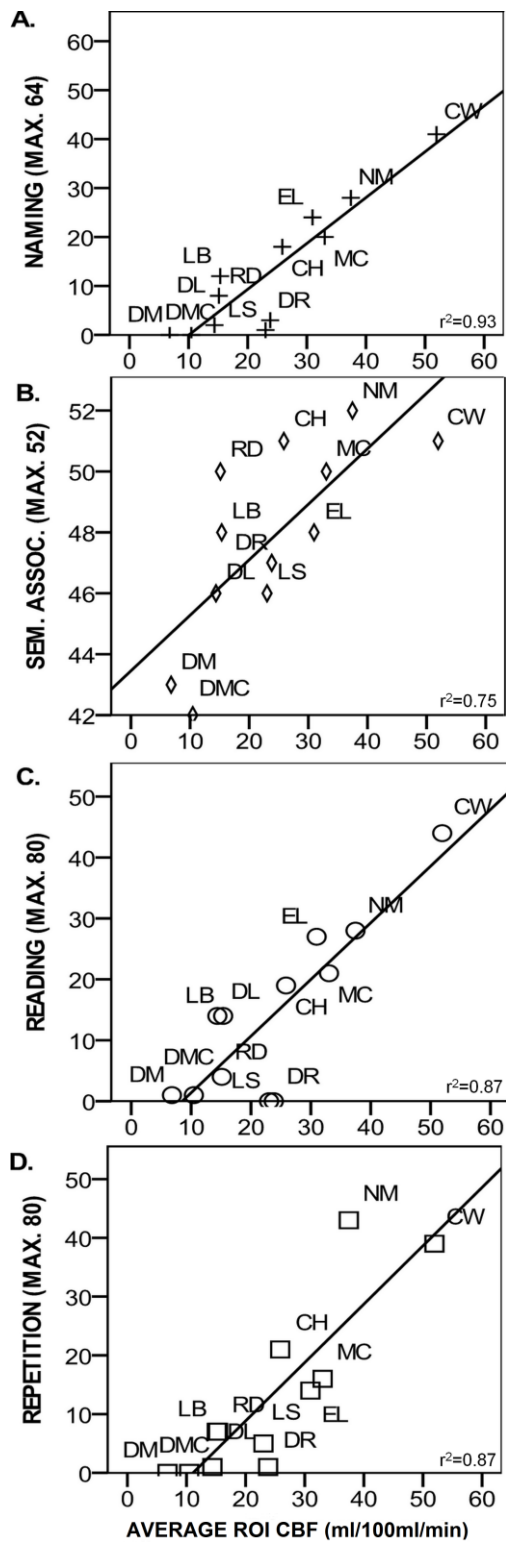
Figure displays participant loading for the WA and control groups on component Six.

3.1.3 Associations with behaviour:

Partial correlations, accounting for time post onset, were performed to identify associations between the mixing coefficient loading of component six and the non-verbal reasoning, semantic, phonological and naming neuropsychological assessment in the WA group. Significant positive correlations were observed between component loading and the phonological assessments (reading and repetition), naming assessment and the semantic association Pyramids and Palm Trees test (repetition, $r^2=0.677$, $p=0.022$; reading aloud $r^2=0.683$, $p=0.021$; naming $r^2=0.703$, $p=0.016$; PPT $r^2=0.649$, $p=0.031$). The mixing coefficient loading for component six was negative for all members of the WA group and positive for all control group members. The correlations indicated that the *less* negative the WA participants or the more “control-like” in loading, the greater accuracy in behavioural assessment.

Although the jICA revealed hypoperfusion beyond the core lesion (Fig. 1B), visual inspection of individual lesion maps (Fig. 1A) indicated that lesions overlapped with this area of extended hypoperfusion, to some extent, in a subset of cases. To investigate whether hypoperfusion in this region made an independent contribution to behavioural impairment, ROI analyses were performed. An ROI was derived from the jICA region of extended hypoperfusion, Fig. 1C. Using the MarsBaR toolbox (Brett, et al., 2002), average CBF (ml/100ml/min) and lesion (probability of CSF in CSF segmented images) values over the ROI were extracted unsmoothed images in the WA group. Partial correlations found significant relationships between the neuropsychological results and CBF but not lesion data (Fig. 3). Independent t-tests using the Fisher-transformation correlation coefficient values indicated significantly different correlation coefficients between each CBF-lesion correlation pair (repetition: CBF $r^2=0.865$, $p=0.001$, lesion $r^2=-0.13$, $p=0.97$; reading CBF $r^2=0.874$, $p<0.001$, lesion $r^2=-0.167$, $p=0.62$; naming CBF $r^2=0.931$, $p<0.001$ lesion $r^2=-0.091$ $p=0.79$; PPT CBF $r^2=0.75$, $p=0.009$, lesion $r^2=-0.131$, $p=0.70$). To support this analysis lesion volume within the ROI was calculated. Lesion volume was taken as the number of voxels of the binary lesion data from the Seghier et al., (2008) automated lesion detection protocol, see above. Within ROI lesion volume was then used as a covariate in partial correlations between CBF and neuropsychological data. All correlations remained significant, with a minimum effect size of $r^2 > 0.62$. To confirm that these strong correlations were not driven by outliers, the two participants with the greatest residual CBF within the ROI were removed and the initial partial correlations were re-run. Strong effect sizes remained for all correlations ($r^2>0.63$) with correlations remaining significant for naming and repetition. Taken together, these correlation ROI analyses indicated that CBF but not lesion in the region surrounding the core lesion showed a systematic relationship with impairment, with greater CBF corresponding to more preserved performance.

Figure 3: Perilesional CBF Correlations with Neuropsychological Results



Scatter plots displaying relationship between CBF (ml/100ml/min) surrounding core area of lesion and neuropsychological test data. Partial correlation coefficients displayed.

4.1 Discussion:

This study investigated patterns of hypoperfusion associated with chronic temporoparietal lesions and Wernicke's Aphasia (WA). A joint independent component analysis (jICA) was used to identify areas where voxels in resting-state arterial spin labelling cerebral blood flow images (CBF) co-varied significantly with voxels from cerebrospinal fluid (CSF) maps, used as a proxy for lesion, and differed significantly from control participants. Correlations with neuropsychological assessments were then performed to investigate how patterns of structural damage and hypoperfusion related to behavioural language impairment. The results found hypoperfusion extending into perilesional areas which, along with the core structural lesion, was associated with aspects of the language impairment. Follow-up correlations indicated that, outside the area of core lesion, hypoperfusion but not lesion was systematically related to behavioural neuropsychological impairment.

The jICA identified a single component for which there was no numerical overlap in mixing coefficient loading between WA and control groups. This component captured a large area of structural lesion in the left temporoparietal region as well as hypoperfusion in overlapping areas. In addition, extensive hypoperfusion was observed perilesionally, in grey matter lateral, anterior and posterior to the core lesion which primarily affected white matter areas. This indicates that these grey matter regions, although not suffering macrostructural damage, are likely to be functionally limited (Gold and Lauritzen, 2002) or suffering microstructural damage. The average rCBF in this "perilesional" region in the WA group was 25.7ml/100ml/min (sd 12.3ml/100ml/min), significantly lower ($t_{(21)}=5.95$, $p<0.001$) than the average rCBF in the control group, 61.8ml/100ml/min (sd 15.9ml/100ml/min). Neuronal tissue will die if CBF falls below approximately 20ml/100ml/min (Jones, et al., 1981). Although the WA group as a whole displayed CBF above this level, a number of individuals displayed CBF below this cut-off, Figure 3, reflecting the extension of infarction into this

region in a subset of participants. Most individuals with WA displayed CBF values within the functional range in this perilesional zone but below that of the controls indicating reduced neuronal function of residual tissue. However, caution must be taken in interpretation of absolute CBF estimates from ASL data due to uncertainty in some of the assumed global variables such as T_1 of blood.

The cause of this perilesional hypoperfusion is unclear. It may represent an area of penumbra which has not undergone re-perfusion or evolution to lesion, as typically observed in the acute-subacute phase (Butcher, et al., 2005; Neumann-Haefelin, et al., 1999). Alternatively, it is credible that the perilesional hypoperfusion observed here has evolved separately following the acute phase through a diaschisis-type mechanism and represents a form of focal diaschisis (Carrera and Tononi, 2014). Under this hypothesis hypoperfusion results from a reduction of coordinated synaptic function because of disconnection and reduced afferent input (Feeney and Baron, 1986). Although acute phase cortico-subcortical diaschisis is common (Bowler, et al., 1995; Carrera and Tononi, 2014), lesion-remote cortico-cortico hypoperfusion has been shown to develop over time in humans following stroke (Iglesias, et al., 1996; Iglesias, et al., 2000). This functional loss could be a consequence of numerous neurobiological processes such as Wallerian-like, retrograde or transynaptic degeneration (Iglesias, et al., 2000).

In contrast to the identification of hypoperfusion in intact grey matter regions, this study also identified regions of structural lesion that were not statistically associated with perfusion changes. These were the most medial regions, adjacent to the lateral ventricle. This pattern is likely to be accounted for by reduced microvascular density (and reduced regional cerebral blood flow) in white matter in comparison to grey matter (Jensen, et al., 2006) and the

reduced signal-to-noise ratio of the ASL signal in white matter regions (van Gelderen, et al., 2008). This could have led to WM hypoperfusion being missed in the ASL analysis and, therefore, perfusion differences between WA and controls in WM regions not being identified as significant in the jICA statistical analysis. As such, the finding of lesion without corresponding hypoperfusion in the jICA analysis is likely to be an artefact of the ASL method. The perilesional and remote hypoperfusion, see below, identified may have implications for recovery. Although most individuals with acute WA display a strong recovery (Pedersen, et al., 2004), WA that persists into the chronic stage is difficult to treat. Although therapeutic input can induce improvement in isolated aspects of the comprehension system (e.g. phonological perception), these improvements often do not generalise to improve comprehension as a whole (Morris, et al., 1996; Woolf, et al., 2014) except in isolated cases (Tessier, et al., 2007). The current group of WA participants were not receiving speech and language therapy at the time of participation but had received treatment prior to their involvement. Strong spontaneous recovery in WA has been associated with enhanced functional activation in right superior temporal regions (Leff, et al., 2002; Weiller, et al., 1995), an area suffering from hypoperfusion in the current group of participants. The hypoperfusion identified in the current study may indicate reduced capacity to engage in local neuroplastic reorganisation processes, potentially contributing to the limited recovery of aphasia symptoms.

The finding of functionally depressed tissue outside the area of core lesion has implications for accounting for the range of neuropsychological impairments observed in WA. Indeed, this study found a relationship between the lesion/hypoperfusion and behavioural impairment. Correlation analyses found that the more “control-like” the WA participants were in their jICA mixing matrix coefficient loading, the better their performance on neuropsychological

assessment. Specifically, the greater the perfusion and the less lesion in the identified regions (Fig. 1C) was associated with better naming, reading, repetition and semantic association. This pattern of correlations is interpretable within current neurobiological models of language. The posterior temporal lobe, inferior parietal lobe and temporoparietaloccipital junction contain important components of both the phonological network (required for reading, repetition and naming tasks) and the semantic network (required for semantic association and naming tasks). Phonological identification and encoding processes take advantage of the high structural connectivity between auditory and motor regions in the superior temporal and inferior parietal lobe (Ueno, et al., 2011), the dorsal language stream. Functional imaging shows consistent activation within this stream during phonological tasks and TMS to the same regions disrupts performance in neurologically normal populations (Hartwigsen, et al., 2015). The semantic network, while extensive and highly distributed, has components in the left middle temporal lobe and angular gyrus. These areas also respond during functional imaging of semantic processing tasks (Noonan, et al., 2013; Seghier, et al., 2010), with TMS to these regions impairing performance (Hoffman, et al., 2011; Whitney, et al., 2010).

Previous lesion-symptom mapping investigations have found similar brain-behaviour relationships to the current study. For example, semantic errors in naming have been associated with lesion in middle temporal regions (Schwartz, et al., 2011) whereas phonological errors are associated with lesions to inferior parietal and dorsal stream regions (Schwartz, et al., 2012). However, the current study extended these findings by exploring the relationship between cerebral blood flow surrounding the core lesion and behavioural impairment. Correlation analyses found a highly significant relationship between perilesional CBF which was not found for CSF/lesion data in the same region. These results indicated

that perilesional hypoperfusion makes an independent contribution to behavioural performance post stroke over-and-above the structural lesion. However, the lesion symptom mapping approach may inherently capture the CBF-neuropsychology relationships uncovered in the current study, although without explicit visualisation. The WA group were highly homogeneous in that all participants displayed lesions which affected the white matter of the middle-superior temporal lobe or inferior parietal cortex to some degree. It is possible that lesions to this region inevitably lead to reductions in temporoparietal grey matter CBF over the long-term post stroke. As such, the CBF correlations in the present study may represent behaviourally-relevant aspects of lesion and correlations in lesion-symptom mapping methods may capture behaviourally-relevant aspects of CBF.

Although the current data broadly converge with lesion-symptom mapping and neuroimaging evidence, it is important to note that the current study does not aim to identify specific brain-behaviour relationships, rather to investigate the wider relationship between lesion, hypoperfusion and behaviour. Mass univariate lesion-symptom mapping approaches suffer from spatial distortion as a consequence of lesion profiles biased by the constraints of the vascular architecture (Mah, et al., 2014). The current study used a multivariate approach designed to identify lesion-hypoperfusion relationships independent of the degree of overlapping damage. However, spatial bias has been reintroduced to this study through the selection of participants with highly overlapping lesion profiles and, as such, this study should not be considered a robust investigation of the neural source of a particular impairment.

The WA participants displayed highly overlapping lesion profiles, constrained by the vascular architecture. This lesion bias introduces spatial distortion into mass univariate lesion-symptom mapping approaches

The correlations between CBF and neuropsychology scores observed in the ROI analysis were particularly strong. This is likely to be a result of the stringent participant selection criteria employed in this study, where a small number of participants were recruited based on narrowly defined behavioural characteristics. The participants in this study all conformed to the classical definition of WA and displayed qualitatively similar impairment patterns in conversation but with a range of severities. This indicates that the results from the current study may be generalizable within classical WA, however the robustness of the CBF and behavioural relationships may breakdown if more diverse patient populations are explored. A further contribution to the correlation strength could have emerged from age-related reorganisation. Occipito-temporo-parietal regions are through to be particularly vulnerable to neuroanatomical and functional decline in ageing (Davis, et al., 2008). Functional imaging has found reduced activation during a range of cognitive tasks in elderly participants in comparison to younger participants (Grossman, et al., 2002; Madden, et al., 2002; Meulenbroek, et al., 2004), including temporal and parietal regions affected by hypoperfusion in the current study.

Evidence for hypoperfusion remote from but causally connected to the lesion, i.e. perfusion changes consistent with the definition of remote focal diaschisis, appeared limited. Only two small regions of hypoperfusion were observed at the group level, the largest in the left cuneus and a small cluster in right mid superior temporal gyrus. The jICA technique identifies regions of consistent lesion-hypoperfusion associations across the group. At the participant

level individual patterns of remote hypoperfusion may be present. In the current study, the cortico-cortico hypoperfusion regions appear limited, however, comparison of neuroimaging techniques in animal models suggest that observed alterations in cerebral perfusion are an underestimation of metabolic changes which, in turn, significantly underestimate alterations in underlying electrical activity (Carmichael, et al., 2004; Gold and Lauritzen, 2002). Therefore, even the limited reduction in cerebral perfusion observed in the current study may reflect considerably reduced neuronal activity.

If we are to consider these results as evidence of cortico-cortico focal diaschisis it raises further important questions about why these particular regions were affected and whether replication would reveal a similar pattern of remote hypoperfusion. While there is previous evidence for remote hypometabolism in WA, this been identified in pre-frontal regions (Metter, et al., 1989) , a pattern not identified in these results. However, evidence exists for structural connectivity, via the inferior fronto-occipital-fasciculus, between the area of lesion and the hypoperfused cuneus region identified in the current study (Martino, et al., 2010). Similarly, the right superior temporal gyrus is connected to the core lesion via the corpus callosum. However the lesion area also has strong interconnectivity with other cortical areas, including inferior frontal and inferior temporal regions (Cloutman, et al., 2013), in which no hypoperfusion effect was detected. Therefore, hypoperfusion as a result of white matter structural disconnection is only speculative at this point. Further investigation should include tractography evidence to investigate the association between remote hypoperfusion and structural connectivity to the area of lesion. Secondly, of the two remote regions of hypoperfusion, only hypoperfusion in the right mid-superior temporal gyrus can be easily associated with the behavioural impairment in WA. Superior temporal regions, bilaterally, are involved in processing auditory stimuli, a cognitive skill which is consistently found to be

impaired in individuals with Wernicke's aphasia (Robson, et al., 2014a). The affected cuneus region plays a role in low and high level visual processing, a well preserved skill in classical WA (Robson, et al., 2012).

One important consideration is that the ASL data were collected during rest. During functioning, the patterns of relative network activation or deactivation are likely to be considerably more complex. Remote diaschisis may be more evident during function, where reduced or absent activity from the area of lesion leads to reduced input/modulation of functionally connected network components. This pattern has been observed in aphasia and termed dynamic diaschisis (Price, et al., 2001). However, it is more common to observe lesion-remote activation increases during task-based functional imaging in aphasia. This pattern was observed in the same group of aphasia participants as in the current study during a functional MRI experiment. During two visual semantic tasks, WA participants were found to have increased and more extensive activation in comparison to control participants in bilateral ventral temporal lobe regions (Robson, et al., 2014b). The combination of results from this previous study and the current study indicate that, in the same patient group, it is possible to observe both extra-lesional diaschisis and remote functional up-regulation. These results support other functional imaging work in aphasia in indicating that the complex patterns of behaviour cannot be explained by structural lesion alone, but rather a combination of lesion and alterations to network dynamics.

Finally, one methodological consideration important for the interpretation of the current results is the method used to identify lesion. In the current study, masked and segmented CSF maps were used to estimate the probability of lesion in a given region. In the acute phase, T1-weighted MRI imaging is not suitable for identifying lesions as the pathological

processes inducing T1-w signal change take time to develop (Davis, et al., 2003). However, in the chronic phase T1-weighted imaging is the most commonly used research tool for identifying stroke lesions (Rekik, et al., 2012) and is advantageous in that it provides high resolution which facilitates normalisation enabling accurate lesion location to be identified. However, it is T2-weighted imaging that is considered the best approach for identifying lesion volume following the acute phase post-stroke (Davis, et al., 2003). Imaging sequences have different sensitivities; T1-weighted MRI, for example, has reduced sensitivity to white matter changes in comparison to FLAIR (Crinion, et al., 2013) and areas of lesion can display similar intensities to non-lesioned tissue (Hojjatoleslami and Kruggel, 2001). Such factors may have led to an underestimate to the lesion in the current study and, therefore, an overestimate of the perilesional lesion-CBF mismatch. Combining multiple imaging modalities can improve the sensitivity of structural lesion delineation (Lu, et al., 2005; Mitra, et al., 2014) and should be considered for future investigations of structural damage and hypoperfusion in chronic stroke.

5.1 Conclusion:

This study used a data-driven statistical method to identify regions of hypoperfusion associated with structural lesion in chronic Wernicke's aphasia. Strong evidence was observed for functionally compromised but structurally intact grey matter regions surrounding the lesion. Additional regions of remote cortical hypoperfusion were also identified which may be indicative of reduced resting-state functional activation in these patients in comparison with a control population. This study indicates that reduced peri-

lesional grey matter function may develop secondary to deep middle-superior temporal white matter lesions and contribute to the behavioural impairments in chronic Wernicke's aphasia.

Acknowledgments: Thanks go to all study participants and their family members and carers who facilitated their involvement.

Funding: This study was supported by a Stroke Association Allied Health Professions Research Bursary (TSAB2008/01), a Stroke Association Senior Research Training Fellowship (TSA SRTF 2012/02) awarded to HR, an MRC clinician scientist fellowship (G0902304) awarded to RZ and an MRC programme grant (MR/J004 146/1) awarded to MALR.

References

- Abel, S., Weiller, C., Huber, W., Willmes, K., Specht, K. (2015) Therapy-induced brain reorganization patterns in aphasia. *Brain*, 138:1097-1112.
- Andrews, R.J. (1991) Transhemispheric diaschisis. A review and comment. *Stroke*, 22:943-9.
- Baker, E., Blumstein, S.E., Goodglass, H. (1981) Interaction between phonological and semantic factors in auditory comprehension. *Neuropsychologia*, 19:1-15.
- Barber, P.A., Consolo, H.K., Yang, Q., Darby, D.G., Desmond, P.M., Lichtenstein, M., Tress, B.M., Davis, S.M. (2001) Comparison of MRI perfusion imaging and single photon emission computed tomography in chronic stroke. *Cerebrovasc Dis*, 11:128-136.
- Binkofski, F., Seitz, R.J., Arnold, S., Classen, J., Benecke, R., Freund, H.J. (1996) Thalamic metabolism and corticospinal tract integrity determine motor recovery in stroke. *Annals of Neurology*, 39:460-470.
- Bowler, J.V., Wade, J.P.H., Jones, B.E., Nijran, K., Jewkes, R.F., Cuming, R., Steiner, T.J. (1995) Contribution of Diaschisis to the Clinical Deficit in Human Cerebral Infarction. *Stroke*, 26:1000-1006.
- Bozeat, S., Lambon Ralph, M.A., Patterson, K., Garrard, P., Hodges, J.R. (2000) Non-verbal semantic impairment in semantic dementia. *Neuropsychologia*, 38:1207-15.
- Brett, M., Anton, J.L., Valabregue, R., Poline, J.B. (2002) Region of interest analysis using the MarsBar toolbox for SPM 99. *NeuroImage*, 16:S497.
- Brumm, K.P., Perthen, J.E., Liu, T.T., Haist, F., Ayalon, L., Love, T. (2010) An arterial spin labeling investigation of cerebral blood flow deficits in chronic stroke survivors. *NeuroImage*, 51:995-1005.

- Butcher, K.S., Parsons, M., MacGregor, L., Barber, P.A., Chalk, J., Bladin, C., Levi, C., Kimber, T., Schultz, D., Fink, J., Tress, B., Donnan, G., Davis, S., Investigators, f.t.E. (2005) Refining the Perfusion–Diffusion Mismatch Hypothesis. *Stroke*, 36:1153-1159.
- Calhoun, V.D., Liu, J., Adali, T. (2009) A review of group ICA for fMRI data and ICA for joint inference of imaging, genetic, and ERP data. *NeuroImage*, 45:S163-S172.
- Carmichael, S.T., Tatsukawa, K., Katsman, D., Tsuyuguchi, N., Kornblum, H.I. (2004) Evolution of Diaschisis in a Focal Stroke Model. *Stroke*, 35:758-763.
- Carrera, E., Tononi, G. (2014) Diaschisis: past, present, future. *Brain*, 137:2408-2422.
- Cloutman, L.L., Binney, R.J., Morris, D.M., Parker, G.J.M., Lambon Ralph, M.A. (2013) Using in vivo probabilistic tractography to reveal two segregated dorsal ‘language-cognitive’ pathways in the human brain. *Brain and Language*, 127:230-240.
- Cohen, R., Kelter, S., Woll, G. (1980) Analytical competence and language impairment in aphasia. *Brain and Language*, 10:331-51.
- Crinion, J., Ashburner, J., Leff, A., Brett, M., Price, C., Friston, K. (2007) Spatial normalization of lesioned brains: Performance evaluation and impact on fMRI analyses. *NeuroImage*, 37:866-875.
- Crinion, J., Holland, A.L., Copland, D.A., Thompson, C.K., Hillis, A.E. (2013) Neuroimaging in aphasia treatment research: Quantifying brain lesions after stroke. *NeuroImage*, 73:208-214.
- Croquelois, A., Wintermark, M., Reichhart, M., Meuli, R., Bogouslavsky, J. (2003) Aphasia in hyperacute stroke: Language follows brain penumbra dynamics. *Annals of Neurology*, 54:321-329.
- Davis, S., Fisher, M., Warach, S. (2003) *Magnetic Resonance Imaging in Stroke*. Cambridge University Press.
- Davis, S.W., Dennis, N.A., Daselaar, S.M., Fleck, M.S., Cabeza, R. (2008) Qué PASA? The Posterior–Anterior Shift in Aging. *Cerebral Cortex*, 18:1201-1209.
- De Renzi, E., Faglioni, P., Scotti, G., Spinnler, H. (1972) Impairment in associating colour to form, concomitant with aphasia. *Brain*, 95:293-304.
- Dronkers, N.F., Wilkins, D.P., Van Valin Jr., R.D., Redfern, B.B., Jaeger, J.J. (2004) Lesion analysis of the brain areas involved in language comprehension. *Cognition*, 92:145-177.
- Edelman, R.R., Siewert, B., Darby, D.G., Thangaraj, V., Nobre, A.C., Mesulam, M.M., Warach, S. (1994) Qualitative mapping of cerebral blood flow and functional localization with echo-planar MR imaging and signal targeting with alternating radio frequency. *Radiology*, 192:513-520.
- Feeney, D.M., Baron, J.C. (1986) Diaschisis. *Stroke*, 17:817-30.
- Girouard, H., Iadecola, C. (2006) Neurovascular coupling in the normal brain and in hypertension, stroke, and Alzheimer disease. *Journal of applied physiology*, 100:328-335.
- Gold, L., Lauritzen, M. (2002) Neuronal deactivation explains decreased cerebellar blood flow in response to focal cerebral ischemia or suppressed neocortical function. *Proceedings of the National Academy of Sciences*, 99:7699-7704.
- Goodglass, H., Kaplan, E., Barresi, B. (2001) *Boston Diagnostic Aphasia Examination*, 3rd Ed, (BDAE). Baltimore Lippincott Williams & Wilkins.
- Grossman, M., Cooke, A., DeVita, C., Alsop, D., Detre, J., Chen, W., Gee, J. (2002) Age-related changes in working memory during sentence comprehension: an fMRI study. *NeuroImage*, 15:302-317.
- Guo, X., Han, Y., Chen, K., Wang, Y., Yao, L. (2012) Mapping joint grey and white matter reductions in Alzheimer's disease using joint independent component analysis. *Neuroscience Letters*, 531:136-141.
- Hartwigsen, G., Weigel, A., Schuschan, P., Siebner, H.R., Weise, D., Classen, J., Saur, D. (2015) Dissociating Parieto-Frontal Networks for Phonological and Semantic Word Decisions: A Condition-and-Perturb TMS Study. *Cerebral Cortex*.

- Hillis, A.E., Wityk, R.J., Barker, P.B., Beauchamp, N.J., Gailloud, P., Murphy, K., Cooper, O., Metter, E.J. (2002) Subcortical aphasia and neglect in acute stroke: the role of cortical hypoperfusion. *Brain*, 125:1094-1104.
- Hillis, A.E., Wityk, R.J., Tuffiash, E., Beauchamp, N.J., Jacobs, M.A., Barker, P.B., Selnes, O.A. (2001) Hypoperfusion of Wernicke's area predicts severity of semantic deficit in acute stroke. *Ann Neurol*, 50:561-6.
- Hoffman, P., Pobric, G., Drakesmith, M., Lambon Ralph, M.A. (2011) Posterior middle temporal gyrus is involved in verbal and non-verbal semantic cognition: Evidence from rTMS. *Aphasiology*, 26:1119-1130.
- Hojjatoleslami, S.A., Kruggel, F. (2001) Segmentation of large brain lesions. *IEEE Transactions on Medical Imaging*, 20:667.
- Howard, D., Patterson, K. (1992) *Pyramids and Palm Trees: a test of semantic access from pictures and words*. Bury Saint Edmunds. Thames Valley Test Company.
- Iglesias, S., Marchal, G., Rioux, P., Beaudouin, V., Hauttement, J., De La Sayette, V., Le Doze, F., Derlon, J., Viader, F., Baron, J. (1996) Do changes in oxygen metabolism in the unaffected cerebral hemisphere underlie early neurological recovery after stroke? A positron emission tomography study. *Stroke*, 27:1192-1199.
- Iglesias, S., Marchal, G., Viader, F., Baron, J.-C. (2000) Delayed Intrahemispheric Remote Hypometabolism. *Cerebrovascular Diseases*, 10:391-402.
- Jensen, J.H., Lu, H., Inglese, M. (2006) Microvessel density estimation in the human brain by means of dynamic contrast-enhanced echo-planar imaging. *Magnetic Resonance in Medicine*, 56:1145-1150.
- Jodzio, K., Gasecki, D., Drumm, D.A., Lass, P., Nyka, W. (2003) Neuroanatomical correlates of the post-stroke aphasias studied with cerebral blood flow SPECT scanning. *Medical science monitor : international medical journal of experimental and clinical research*, 9:Mt32-41.
- Jones, T.H., Morawetz, R.B., Crowell, R.M., Marcoux, F.W., FitzGibbon, S.J., DeGirolami, U., Ojemann, R.G. (1981) Thresholds of focal cerebral ischemia in awake monkeys. *Journal of neurosurgery*, 54:773-782.
- Kay, J., Coltheart, M., Lesser, R. (1992) *Psycholinguistic Assessments of Language Processing in Aphasia (PALPA)*. Hove, UK: Laurence Erlbaum Associates.
- Leff, A., Crinion, J., Scott, S., Turkheimer, F., Howard, D., Wise, R. (2002) A physiological change in the homotopic cortex following left posterior temporal lobe infarction. *Annals of neurology*, 51:553-558.
- Lu, M., Mitsias, P.D., Ewing, J.R., Soltanian-Zadeh, H., Bagher-Ebadian, H., Zhao, Q., Oja-Tebbe, N., Patel, S.C., Chopp, M. (2005) Predicting final infarct size using acute and subacute multiparametric MRI measurements in patients with ischemic stroke. *Journal of Magnetic Resonance Imaging*, 21:495-502.
- MacIntosh, B.J., Lindsay, A.C., Kylintireas, I., Kuker, W., Günther, M., Robson, M.D., Kennedy, J., Choudhury, R.P., Jezzard, P. (2010) Multiple Inflow Pulsed Arterial Spin-Labeling Reveals Delays in the Arterial Arrival Time in Minor Stroke and Transient Ischemic Attack. *American Journal of Neuroradiology*, 31:1892-1894.
- Madden, D.J., Turkington, T.G., Provenzale, J.M., Denny, L.L., Langley, L.K., Hawk, T.C., Coleman, R.E. (2002) Aging and attentional guidance during visual search: functional neuroanatomy by positron emission tomography. *Psychology and aging*, 17:24.
- Mah, Y.-H., Husain, M., Rees, G., Nachev, P. (2014) Human brain lesion-deficit inference remapped. *Brain*, 137:2522.
- Martino, J., Brogna, C., Robles, S.G., Vergani, F., Duffau, H. (2010) Anatomic dissection of the inferior fronto-occipital fasciculus revisited in the lights of brain stimulation data. *Cortex*, 46:691-699.

- Metter, E.J., Kempler, D., Jackson, C., Hanson, W.R., Mazziotta, J.C., Phelps, M.E. (1989) Cerebral glucose metabolism in Wernicke's, Broca's, and conduction aphasia. *Archives of Neurology*, 46:27-34.
- Meulenbroek, O., Petersson, K.M., Voermans, N., Weber, B., Fernández, G. (2004) Age differences in neural correlates of route encoding and route recognition. *Neuroimage*, 22:1503-1514.
- Mitra, J., Bourgeat, P., Fripp, J., Ghose, S., Rose, S., Salvado, O., Connelly, A., Campbell, B., Palmer, S., Sharma, G., Christensen, S., Carey, L. (2014) Lesion segmentation from multimodal MRI using random forest following ischemic stroke. *NeuroImage*, 98:324-335.
- Morris, J., Franklin, S., Ellis, A.W., Turner, J.E., Bailey, P.J. (1996) Remediating a speech perception deficit in an aphasic patient. *Aphasiology*, 10:137-158.
- Neumann-Haefelin, T., Wittsack, H.-J., Wenserski, F., Siebler, M., Seitz, R.J., Mödder, U., Freund, H.-J. (1999) Diffusion- and Perfusion-Weighted MRI: The DWI/PWI Mismatch Region in Acute Stroke. *Stroke*, 30:1591-1597.
- Noonan, K.A., Jefferies, E., Visser, M., Lambon Ralph, M.A. (2013) Going beyond Inferior Prefrontal Involvement in Semantic Control: Evidence for the Additional Contribution of Dorsal Angular Gyrus and Posterior Middle Temporal Cortex. *Journal of Cognitive Neuroscience*, 25:1824-1850.
- Ogar, J.M., Baldo, J.V., Wilson, S.M., Brambati, S.M., Miller, B.L., Dronkers, N.F., Gorno-Tempini, M.L. (2011) Semantic dementia and persisting Wernicke's aphasia: Linguistic and anatomical profiles. *Brain and Language*, 117:28-33.
- Parkes, L.M., Rashid, W., Chard, D.T., Tofts, P.S. (2004) Normal cerebral perfusion measurements using arterial spin labeling: Reproducibility, stability, and age and gender effects. *Magnetic Resonance in Medicine*, 51:736-743.
- Pedersen, P.M., Vinter, K., Olsen, T.S. (2004) Aphasia after stroke: Type, severity and prognosis - The Copenhagen aphasia study. *Cerebrovascular Diseases*, 17:35-43.
- Price, C.J., Warburton, E.A., Moore, C.J., Frackowiak, R.S.J., Friston, K.J. (2001) Dynamic Diaschisis: Anatomically Remote and Context-Sensitive Human Brain Lesions. *Journal of Cognitive Neuroscience*, 13:419-429.
- Rachakonda, S., Liu, J., Calhoun, V.D. (2012) Fusion ICA Toolbox (FIT) Manual.
- Raven, J.C. (1962) Coloured Progressive Matrices Sets A, AB, B. London. H. K. Lewis.
- Raynaud, C., Rancurel, G., Samson, Y., Baron, J.C., Soucy, J.P., Kieffer, E., Cabanis, E., Majdalani, A., Ricard, S., Bardy, A. (1987) Pathophysiologic study of chronic infarcts with I-123 isopropyl iodo-amphetamine (IMP): the importance of periinfarct area. *Stroke*, 18:21-9.
- Rekik, I., Allassonnière, S., Carpenter, T.K., Wardlaw, J.M. (2012) Medical image analysis methods in MR/CT-imaged acute-subacute ischemic stroke lesion: Segmentation, prediction and insights into dynamic evolution simulation models. A critical appraisal. *NeuroImage: Clinical*, 1:164-178.
- Roberts, D.A., Rizi, R., Lenkinski, R.E., Leigh, J.S. (1996) Magnetic resonance imaging of the brain: Blood partition coefficient for water: Application to spin-tagging measurement of perfusion. *Journal of Magnetic Resonance Imaging*, 6:363-366.
- Robson, H., Cloutman, L., Keidel, J.L., Sage, K., Drakesmith, M., Welbourne, S. (2014a) Mismatch negativity (MMN) reveals inefficient auditory ventral stream function in chronic auditory comprehension impairments. *Cortex*, 59:113-125.
- Robson, H., Grube, M., Lambon Ralph, M.A., Griffiths, T.D., Sage, K. (2013) Fundamental deficits of auditory perception in Wernicke's aphasia. *Cortex*, 49:1808-1822.
- Robson, H., Sage, K., Lambon Ralph, M.A. (2012) Wernicke's aphasia reflects a combination of acoustic-phonological and semantic control deficits: A case-series comparison of Wernicke's aphasia, semantic dementia and semantic aphasia. *Neuropsychologia*, 50:266-275.
- Robson, H., Zahn, R., Keidel, J.L., Binney, R.J., Sage, K., Lambon Ralph, M.A. (2014b) The anterior temporal lobes support residual comprehension in Wernicke's aphasia. *Brain*, 137:931-943.

- Schwartz, M.F., Faseyitan, O., Kim, J., Coslett, H.B. (2012) The dorsal stream contribution to phonological retrieval in object naming. *Brain*, 135:3799-3814.
- Schwartz, M.F., Kimberg, D.Y., Walker, G.M., Brecher, A., Faseyitan, O.K., Dell, G.S., Mirman, D., Coslett, H.B. (2011) Neuroanatomical dissociation for taxonomic and thematic knowledge in the human brain. *Proceedings of the National Academy of Sciences*, 108:8520-8524.
- Seghier, M.L., Fagan, E., Price, C.J. (2010) Functional Subdivisions in the Left Angular Gyrus Where the Semantic System Meets and Diverges from the Default Network. *The Journal of Neuroscience*, 30:16809-16817.
- Seghier, M.L., Ramlakhansingh, A., Crinion, J., Leff, A.P., Price, C.J. (2008) Lesion identification using unified segmentation-normalisation models and fuzzy clustering. *Neuroimage*, 41:1253-1266.
- Seitz, R.J., Azari, N.P., Knorr, U., Binkofski, F., Herzog, H., Freund, H.-J. (1999) The Role of Diaschisis in Stroke Recovery. *Stroke*, 30:1844-1850.
- Specht, K., Zahn, R., Willmes, K., Weis, S., Holtel, C., Krause, B.J., Herzog, H., Huber, W. (2009) Joint independent component analysis of structural and functional images reveals complex patterns of functional reorganisation in stroke aphasia. *NeuroImage*, 47:2057-2063.
- Stanisz, G.J., Odobina, E.E., Pun, J., Escaravage, M., Graham, S.J., Bronskill, M.J., Henkelman, R.M. (2005) T1, T2 relaxation and magnetization transfer in tissue at 3T. *Magnetic Resonance in Medicine*, 54:507-512.
- Stone, J.V. (2005) Independent Component Analysis. *Encyclopedia of Statistics in Behavioral Science*: John Wiley & Sons, Ltd.
- Tessier, C., Weill-Chounlamountry, A., Michelot, N., Pradat-Diehl, P. (2007) Rehabilitation of word deafness due to auditory analysis disorder. *Brain Injury*, 21:1165-1174.
- Toni, D., Fiorelli, M., Bastianello, S., Falcou, A., Sette, G., Ceschin, V., Sacchetti, M.L., Argentino, C. (1997) Acute Ischemic Strokes Improving During the First 48 Hours of Onset: Predictability, Outcome, and Possible Mechanisms: A Comparison With Early Deteriorating Strokes. *Stroke*, 28:10-14.
- Ueno, T., Saito, S., Rogers, Timothy T., Lambon Ralph, Matthew A. (2011) Lichtheim 2: Synthesizing Aphasia and the Neural Basis of Language in a Neurocomputational Model of the Dual Dorsal-Ventral Language Pathways. *Neuron*, 72:385-396.
- van Gelderen, P., de Zwart, J.A., Duyn, J.H. (2008) Pitfalls of MRI measurement of white matter perfusion based on arterial spin labeling. *Magnetic Resonance in Medicine*, 59:788-795.
- Weiller, C., Isensee, C., Rijntjes, M., Huber, W., Müller, S., Bier, D., Dutschka, K., Woods, R.P., Noth, J., Diener, H.C. (1995) Recovery from Wernicke's aphasia: a positron emission tomographic study. *Annals of neurology*, 37:723-732.
- Whitney, C., Kirk, M., O'Sullivan, J., Lambon Ralph, M.A., Jefferies, E. (2010) The Neural Organization of Semantic Control: TMS Evidence for a Distributed Network in Left Inferior Frontal and Posterior Middle Temporal Gyrus. *Cerebral Cortex*.
- Woolf, C., Panton, A., Rosen, S., Best, W., Marshall, J. (2014) Therapy for auditory processing impairment in aphasia: An evaluation of two approaches. *Aphasiology*, 28:1481-1505.

List of Tables and Figures:

Table I: Participant Demographics

Table II: Neuropsychological Assessment Results

Figure 1: Lesion Overlap Map, CBF map and jICA Results for Component Six.

Figure 2: Component Six Mixing Matrix Loading

Figure 3: Perilesional CBF Correlations with Neuropsychological Results