

Catabolic cytokine expression in degenerate and herniated human intervertebral discs: IL-1 β and TNF α expression profile.

LE MAITRE, Christine Lyn <<http://orcid.org/0000-0003-4489-7107>>, HOYLAND, Judith Alison and FREEMONT, Anthony J

Available from Sheffield Hallam University Research Archive (SHURA) at:

<https://shura.shu.ac.uk/9957/>

This document is the Published Version [VoR]

Citation:

LE MAITRE, Christine Lyn, HOYLAND, Judith Alison and FREEMONT, Anthony J (2007). Catabolic cytokine expression in degenerate and herniated human intervertebral discs: IL-1 β and TNF α expression profile. *Arthritis research & therapy*, 9 (4), R77. [Article]

Copyright and re-use policy

See <http://shura.shu.ac.uk/information.html>

Research article

Open Access

Catabolic cytokine expression in degenerate and herniated human intervertebral discs: IL-1 β and TNF α expression profile

Christine Lyn Le Maitre, Judith Alison Hoyland and Anthony J Freemont

Tissue Injury and Repair Group, School of Medicine, Faculty of Medical and Human Sciences, The University of Manchester, Oxford Road, Manchester M13 9PT, UK

Corresponding author: Judith Alison Hoyland, judith.hoyland@manchester.ac.uk

Received: 15 May 2007 Revisions requested: 28 Jun 2007 Revisions received: 10 Jul 2007 Accepted: 9 Aug 2007 Published: 9 Aug 2007

Arthritis Research & Therapy 2007, **9**:R77 (doi:10.1186/ar2275)This article is online at: <http://arthritis-research.com/content/9/4/R77>© 2007 Le Maitre *et al.*; licensee BioMed Central Ltd.This is an open access article distributed under the terms of the Creative Commons Attribution License (<http://creativecommons.org/licenses/by/2.0>), which permits unrestricted use, distribution, and reproduction in any medium, provided the original work is properly cited.**Abstract**

Low back pain is a common and debilitating disorder. Current evidence implicates intervertebral disc (IVD) degeneration and herniation as major causes, although the pathogenesis is poorly understood. While several cytokines have been implicated in the process of IVD degeneration and herniation, investigations have predominately focused on Interleukin 1 (IL-1) and tumor necrosis factor alpha (TNF α). However, to date no studies have investigated the expression of these cytokines simultaneously in IVD degeneration or herniation, or determined which may be the predominant cytokine associated with these disease states. Using quantitative real time PCR and immunohistochemistry we investigated gene and protein expression for IL-1 β , TNF α and their receptors in non-degenerate, degenerate and herniated human IVDs. IL-1 β gene expression was observed in a greater proportion of IVDs than TNF α (79% versus 59%). Degenerate and herniated IVDs displayed higher levels of both cytokines than non-degenerate IVDs, although in degenerate IVDs higher levels of IL-1 β gene expression (1,300 copies/100 ng cDNA)

were observed compared to those of TNF α (250 copies of TNF α /100 ng cDNA). Degenerate IVDs showed ten-fold higher IL-1 receptor gene expression compared to non-degenerate IVDs. In addition, 80% of degenerate IVD cells displayed IL-1 receptor immunopositivity compared to only 30% of cells in non-degenerate IVDs. However, no increase in TNF receptor I gene or protein expression was observed in degenerate or herniated IVDs compared to non-degenerate IVDs. We have demonstrated that although both cytokines are produced by human IVD cells, IL-1 β is expressed at higher levels and in more IVDs, particularly in more degenerate IVDs (grades 4 to 12). Importantly, this study has highlighted an increase in gene and protein production for the IL-1 receptor type I but not the TNF receptor type I in degenerate IVDs. The data thus suggest that although both cytokines may be involved in the pathogenesis of IVD degeneration, IL-1 may have a more significant role than TNF α , and thus may be a better target for therapeutic intervention.

Introduction

Intervertebral disc (IVD) degeneration and IVD herniation are major causes of low back pain (LBP) [1], which is a common, debilitating and economically important disorder [2,3]. However, none of the current treatments for LBP are directed at the altered cell and matrix biology underlying IVD degeneration or IVD herniation. Recent advances in therapeutics, particularly cell and tissue engineering, offer potential methods for inhibiting or reversing IVD degeneration, which has not previously been possible. However, the pathogenesis of IVD degeneration and IVD herniation is still not fully understood, and a greater understanding is necessary before such therapies can be fully developed for successful translation in the clinic.

The cells of the IVD behave abnormally during IVD degeneration, with decreased synthesis of the normal IVD matrix and

increased production of degradative enzymes leading to a loss of the normal homeostatic metabolism in the IVD [4-7]. As a result there is destruction of the matrix with loss of hydration, resulting in spinal instability and a reduced ability to withstand load. Furthermore, IVD degeneration can also precede herniation of the IVD, which results in local nerve irritation, inflammation and further pain. In addition to the matrix degrading enzymes, these catabolic processes are thought to be mediated by a number of soluble mediators, including IL-1, tumour necrosis factor TNF α , IL-6, IL-8 and prostaglandin E₂ [8-10].

Of these, the cytokines IL-1 and TNF α have been the focus of a number of studies investigating the pathogenesis of IVD degeneration, herniation and sciatic pain [11-20]. TNF α has been linked to IVD herniation and nerve irritation by a number of studies and the outcome of recent experiments using TNF α

inhibitors has implicated this cytokine as an important mediator in LBP [15-20], whilst IL-1 has been shown to be directly involved in the decreased matrix synthesis and increased matrix degradation associated with IVD degeneration [12]. Importantly, elevated levels of IL-1 and TNF α have been found in aged and degenerative IVDs from both animal models and humans [12,21,22]. We have previously demonstrated the synthesis of IL-1 α , IL-1 β , IL-1 receptor type I (RI), IL-1 β converting enzyme and IL-1Ra by the resident chondrocyte-like cells in human IVDs with significant increases in IL-1 α , IL-1 β , IL-1RI and IL-1 β converting enzyme, but not IL-1Ra, during IVD degeneration [12]. Weiler and colleagues [21] found a positive correlation between TNF α and IVD degeneration, with approximately 80% of nucleus pulposus (NP) and 75% of annulus fibrosus (AF) cells staining positively for this cytokine. However, although Weiler and colleagues demonstrated an increase in TNF α immunopositivity in surgical samples compared to autopsy controls, the surgical samples were derived from a mixture of both herniated and degenerate IVDs and, thus, it was unclear from this study whether increased TNF α immunopositivity was observed in both disorders or just in herniation [21]. A recent study by Bachmeier and colleagues [22] also investigated the protein expression of TNF α , TNF receptors and the TNF α activating enzyme TACE in human IVD and demonstrated expression of all four molecules. Interestingly, although TNF α receptors were observed in autopsy samples, no results were presented for TNF receptor expression in surgical samples, thus raising the question as to whether TNF α is biologically active in such samples [22].

Thus, to date, it is not apparent whether both cytokines are involved in IVD degeneration or herniation and, if so, whether one has a predominant role in each disease state, an important question if future therapies are to be successful at targeting the processes involved in IVD degeneration and herniation.

Here, we use fully quantitative real time PCR and immunohistochemistry to investigate the gene and protein expression of IL-1 β , TNF α and their receptors in non-degenerate, degenerate and herniated human IVDs to investigate whether both cytokines are expressed during IVD degeneration and herniation, and whether one may have a more predominant role.

Materials and methods

Tissue selection and grading of IVDs

Human IVD tissue was obtained either at surgery or post-mortem examination with informed consent of the patient or relatives. Local research ethics committee approval was given for this work by the following Local Research Ethics Committees: Salford and Trafford (Project number O1049), Bury and Rochdale (BRLREC 175(a) and (b)), Central Manchester (Ref No: C/01/008) and her Majesty's coroner (LMG/RJ/M6).

Post-mortem tissue

Previous studies have shown that IVD cells remain viable for at least 48 hours following death. In all, 8 IVDs were recovered from 6 patients within 18 hours of death (Table 1). They consisted of full thickness wedges of IVD of 120° of arc removed anteriorly, allowing well-orientated blocks of tissue to be cut for histological study. Patients with a history of sciatica or low back pain sufficient to warrant seeking medical opinion, were excluded from the study.

Degenerate IVD tissue

Patients were selected on the basis of MRI diagnosed degeneration and progression to anterior resection either for spinal fusion or IVD replacement surgery for chronic low back pain. Patients experiencing classical sciatica were excluded from the study. Some patients underwent fusion at more than one level because of instability.

Herniated IVD samples

Patients were selected on the basis of MRI diagnosed IVD herniation and progression to surgery for LBP for removal of the herniated material.

General procedure for tissue specimens for immunohistochemical analysis

A block of tissue, incorporating AF and NP in continuity (or fragments of IVD for herniated samples), was fixed in 10% neutral buffered formalin and processed to paraffin wax. As some specimens contained bone, all the samples were decalcified in EDTA until radiologically decalcified. Sections were taken for haematoxylin and eosin staining to score the degree of morphological degeneration according to previously published criteria [6]. In brief, sections were scored for the presence of cell clusters, fissures, loss of demarcation and haematoxophilia (indicating reduced proteoglycan content): a score of 0 to 3 indicates a histologically normal (non-degenerate) IVD and a grade of 5 to 12 indicates evidence of degeneration. Tissue samples from 39 IVDs were selected for immunohistochemical analysis; these consisted of 8 non-degenerate IVDs (3 post-mortem samples and 5 surgical samples from patients where multiple disc levels were removed due to spinal instability), 22 degenerate IVDs (5 post-mortem samples and 17 surgical samples) and 9 herniated IVDs (all surgical) (Table 1).

General procedure for tissue specimens for gene expression analysis

Tissue samples were divided into two and half the tissue incorporating AF and NP in continuity where present (or fragments of IVD for herniated samples) was taken for grading as described previously. Remaining tissue was separated into NP and AF tissue where both were present, finely minced and digested with 2 U/ml protease (Sigma, Poole, UK) in DMEM + F12 media for 30 minutes at 37°C and washed twice in DMEM + F12. NP cells were isolated in 2 mg/ml collagenase

Table 1**Patient details and grades of tissues used for immunohistochemical analysis**

Laboratory number	Source	Sex	Age (years)	MRI diagnosis	IVD level	Histological grade
1	PM	M	53	Not applicable	L4/5	1
2	PM	M	53	Not applicable	L5/S1	1
3	Surgical	M	44	Relatively normal	L4/5	1
4	Surgical	M	47	Relatively normal	L4/5	2
5	PM	M	75	Not applicable	L5/S1	3
6	Surgical	M	35	Mild degeneration	L5/S1	3
7	Surgical	M	48	Mild degeneration	L3/4	3
8	Surgical	F	64	Mild degeneration	L5/S1	3
9	Surgical	M	46	Normal	L5/S1	4
10	Surgical	M	21	Mild degeneration	L5/S1	4
11	Surgical	F	36	Mild degeneration	L5/S1	4
12	Surgical	M	25	Degenerate	L4/5	5
13	Surgical	F	32	Degenerate	L5/S1	5
14	Surgical	F	36	Degenerate	L4/5	5
15	Surgical	M	25	Degenerate	L4/5	5
16	Surgical	F	35	Degenerate	L4/5	6
17	Surgical	M	39	Degenerate	L4/5	6
18	PM	F	73	Not applicable	L5/S1	6
19	Surgical	M	25	Degenerate	L5/S1	6
20	Surgical	F	55	Degenerate	L5/S1	7
21	PM	F	Not known	Not applicable	L4/5	7
22	Surgical	F	58	Degenerate	L2/3	7
23	Surgical	M	34	Degenerate	L4/5	8
24	Surgical	F	24	Degenerate	L5/S1	8
25	Surgical	F	33	Severe degeneration	L5/S1	9
26	PM	F	73	Not applicable	L4/5	9
27	Surgical	M	68	Severe degeneration	L5/S1	10
28	PM	M	47	Not applicable	L5/S1	10
29	PM	M	47	Not applicable	L5/S1	11
30	Surgical	M	39	Severe degeneration	L4/5	12
31	Surgical	M	26	Herniated IVD	L5/S1	6
32	Surgical	F	43	Herniated IVD	L5/S1	7
33	Surgical	F	39	Herniated IVD	L4/5	7
34	Surgical	F	25	Herniated IVD	L5/S1	7
35	Surgical	M	35	Herniated IVD	L4/5	7
36	Surgical	M	44	Herniated IVD	L5/S1	9
37	Surgical	M	64	Herniated IVD	L5/S1	9
38	Surgical	M	28	Herniated IVD	L4/5	9
39	Surgical	F	45	Herniated IVD	L5/S1	10

IVD, intervertebral disc; F, female; M, male; PM, post-mortem.

type 1 (Gibco, Paisley, UK) for 4 hours at 37°C. (Previous studies have shown 4 hour collagenase treatment does not affect gene expression in IVD cells (data not shown)). Immediately following cell extraction, RNA was extracted with Trizol® reagent (Invitrogen, Paisley, UK) and cDNA synthesized using Bioscript RNase H minus reverse transcriptase (Bioline Ltd, London, UK) and random hexamers (Roche, East Sussex, UK). RNA was extracted and cDNA synthesized from 64 lumbar IVD samples (NP and AF samples) for gene expression analysis (consisting of 24 non-degenerate (aged 37 to 61 years, mean age 51 years), 26 degenerate (aged 28 to 64 years, mean age 44.07 years) and 14 herniated (aged 20 to 51 years, mean age 29.15 years)).

Gene expression for IL-1 and TNF α and their cytokines in human IVDs

Real time PCR was performed for genes encoding IL-1 β , TNF α , IL-1 RI and TNF RI and the housekeeping gene 18s.

Primers and probe design

Primers and probes were designed using the Primer Express program (Applied Biosystems, Warrington, UK) within a single exon to allow detection of target genes in genomic DNA and cDNA samples. Total gene specificity was confirmed by BLAST searches (GenBank database sequences). Primers and probes were purchased from Applied Biosystems (Table 2).

PCR amplification and quantification

PCR reactions were performed and monitored using the ABI Prism 7000 Sequence detection System (Applied Biosystems) as described previously [23]. For each gene, Taqman quantitative PCR was applied to 100 ng cDNA from each sample and genomic standard curve included on each real time plate. Copy number of each gene was determined by reference to the standard curve, generated from the genomic DNA standards. Copy numbers were then normalized to the real time expression of the housekeeping gene 18s as described previously [23]. Mann Whitney U tests were per-

formed to analyse statistical differences between disease states for each gene investigated.

Production and localisation of IL-1 β , TNF α and their receptors in human IVD

Immunohistochemistry was used to localise IL-1 β , TNF α and their active receptors in 39 IVD samples (Table 1). The immunohistochemistry protocol followed was as previously published [12]. Briefly, 4 μ m paraffin sections were dewaxed, rehydrated and endogenous peroxidase blocked using hydrogen peroxide. After washing in dH₂O, sections were then treated with chymotrypsin enzyme antigen retrieval system (0.01% w/v chymotrypsin (Sigma), 20 minutes at 37°C) for IL-1 β , TNF α and TNF RI. No enzyme retrieval was necessary for IL-1 RI. Following washing, non-specific binding sites were blocked at room temperature for 45 minutes with either: 20% w/v rabbit serum (Sigma) for TNF α , IL-1 RI and TNF RI; or 20% w/v donkey serum (Sigma) for IL-1 β . Sections were incubated overnight at 4°C with mouse monoclonal primary antibodies against human TNF α (1:100 dilution; AbCam, Cambridge, UK), IL-1 RI (1:50 dilution; R&D Systems, Abingdon, UK), TNF RI (1:10 dilution; R&D Systems) and goat polyclonal primary antibodies against human IL-1 β (1:300 dilution; SantaCruz, Santa Cruz, CA, USA). Negative controls in which mouse or goat IgGs (Dako, Cambridgeshire, UK) replaced the primary antibody (at an equal protein concentration) were used.

After washing, sections reacted with mouse monoclonal antibodies were incubated in biotinylated rabbit anti-mouse antiserum (1:400; Dako), and sections reacted with goat polyclonal primary antibodies were incubated in a 1:300 dilution of biotinylated donkey anti-goat antiserum (SantaCruz), all for 30 minutes at room temperature. Disclosure of secondary antibody binding was by the streptavidin-biotin complex (Dako) technique with 3,3'-diaminobenzidine tetrahydrochloride solution (Sigma). Sections were counterstained with Mayers Haematoxylin (Raymond A Lamb, East Sussex, UK), dehydrated and mounted in XAM (BDH, Liverpool, UK).

Table 2

PCR primer and probe sequences and efficiencies

Target	Forward primer	Probe	Reverse primer	Efficiency (percent)
18s	PDAR	PDAR	PDAR	99.65
IL-1 β	5' CGG CCA CAT TTG GTT CTA AGA 3'	5' ACC CTC TGT CAT TCG CTC CCA CA 3'	5' AGG GAA GCG GTT GCT CAT C 3'	90.5
TNF α	5' TGG TGG TCT TGT TGC TTA AAG TTC 3'	5' TCC CCT GCC CCA ATC CCT TTA TTA CCC G 3'	5' CGA ACA TCC AAC CTT CCC AAA C 3'	90.1
IL-1 RI	5' ATT TCT GGC TTC TAG TCT GGT GTT C 3'	5' ACT TGA TTT CAG GTG AAT AAC GGT CCC C 3'	5' AAC GTG CCA GTG TGG AGT GA 3'	98.5
TNF RI	5' CCT GGC CCC AAA CCC AAG 3'	5' TTC AGT CCC ACT CCA GGC TTC ACC C 3'	5' GTA TAG GTG GAG CTG GAG GTG 3'	93.8

RI, receptor type I; TNF, tumour necrosis factor. PDAR, Pre-developed assay reagents.

Table 3**Summary of gene and protein expression differences seen compared to non-degenerate discs**

Target	Gene expression	Protein expression
IL-1β		
Degenerate discs	Proportion of samples \uparrow and level \uparrow ($P < 0.05$)	\uparrow in NP and IAF ($P < 0.05$)
Herniated discs	Proportion of samples \uparrow ($P < 0.05$)	\uparrow in NP and IAF ($P < 0.05$)
IL-1 receptor		
Degenerate discs	Proportion of samples \uparrow and level \uparrow ($P < 0.05$)	\uparrow in NP ($P < 0.05$)
Herniated discs	Proportion of samples NC, level \uparrow ($P > 0.05$)	\uparrow in NP ($P < 0.05$)
TNFα		
Degenerate discs	Proportion of samples \uparrow ($P < 0.05$), level NC	\uparrow in NP and IAF ($P < 0.05$)
Herniated discs	Proportion of samples \uparrow ($P < 0.05$), level NC	\uparrow in NP ($P < 0.05$)
TNF receptor		
Degenerate discs	Proportion of samples NC, level \downarrow ($P < 0.05$)	\downarrow in NP and IAF ($P > 0.05$)
Herniated discs	Proportion of samples \downarrow ($P < 0.05$), level NC	\downarrow in NP ($P > 0.05$)

Up and down arrows indicate increase and decrease, respectively. IAF, inner annulus fibrosus; NC, no change; NP, nucleus pulposus.

Image and statistical analysis

All slides were visualised using a Leica RMDB research microscope and images captured using a digital camera and Bioquant Nova image analysis system. Each section was divided into the NP, inner AF (IAF) and outer AF (OAF) where present, and analysed separately. Within each area 200 cells were counted and the number of immunopositive cells (brown staining) expressed as a proportion of this. Data were non-parametric and hence Mann Whitney U tests were performed to compare the numbers of immunopositive cells in degenerate and herniated groups to non-degenerate IVDs (scores 0 to 3) for each area of the IVD. In addition, Wilcoxon paired sample tests were used to compare proportions of immunopositive cells in the different areas of the IVDs. This analysis was performed using all IVD sections regardless of disease state.

Results**Gene expression of IL-1 and TNF and their receptors in non-degenerate human IVDs**

IL-1 β was expressed in more non-degenerate IVDs than those expressing TNF α (63% versus 13%). TNF α was expressed only in IVDs expressing IL-1 β . By comparison, only 58% of non-degenerate samples displayed IL-1 RI gene expression compared to 100% of samples displaying TNF RI gene expression. In addition, samples where gene expression was seen for the receptors demonstrated higher copy numbers for TNF RI (1,087 copies/100 ng cDNA) than IL-1 RI (386 copies/100 ng cDNA) (Figure 1).

Gene expression of IL-1 and TNF and their receptors in degenerate human IVDs

The proportion of IVD cells expressing IL-1 β and TNF α genes was greater in degenerate (100% and 96%, respectively) than

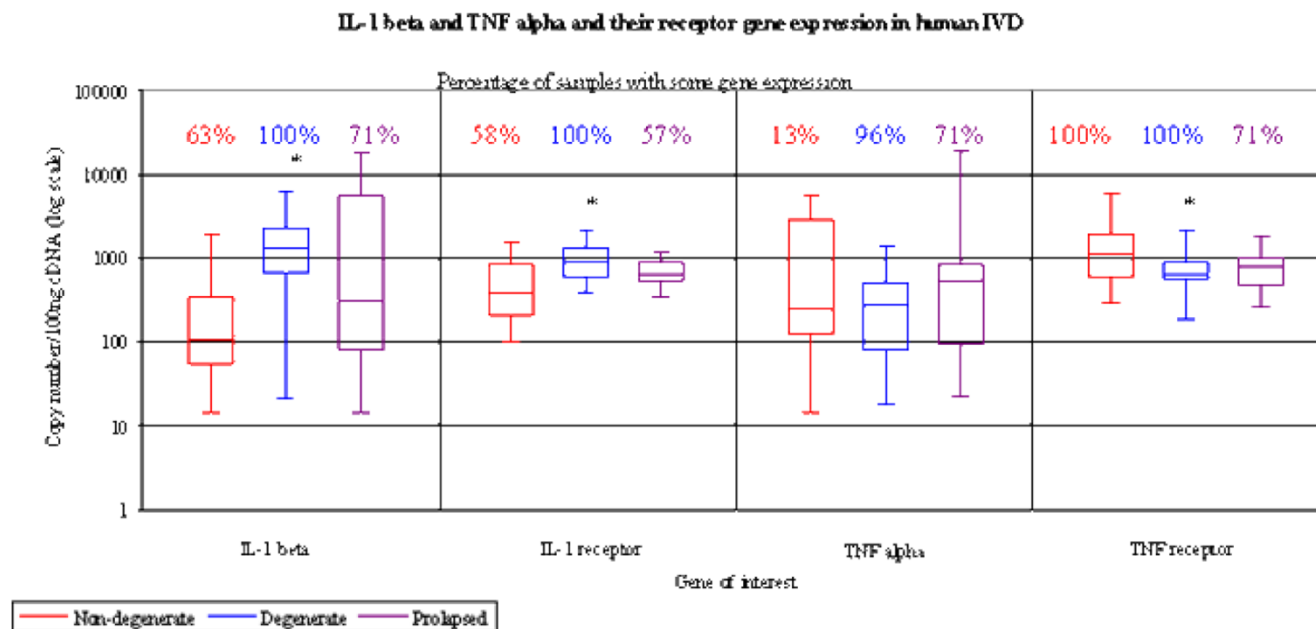
non-degenerate IVDs (63% and 13%, respectively). IL-1 β gene copy number was greater in degenerate than non-degenerate IVDs ($P < 0.05$; Figure 1, Table 3), whereas there was no difference in TNF α copy number between non-degenerate and degenerate IVDs (Figure 1). In degenerate IVDs, the mean copy number was greater for IL-1 β than TNF α (median of 1,298 copies of IL-1 β gene/100 ng cDNA, and 277 copies of TNF alpha/100 ng cDNA; Figure 1).

All degenerate IVDs expressed the genes for both cytokine receptors. This represented an increase over non-degenerate samples in the number of cases expressing the IL-1 RI gene (100% compared to 58%; Figure 1, Table 3). Degenerate IVDs also demonstrated significantly higher copy numbers for IL-1 RI than receptor positive non-degenerate IVDs (906 copies/100 ng cDNA in degenerate IVDs versus 386 copies/100 ng cDNA in non-degenerate IVDs; $P < 0.05$; Figure 1, Table 3). As for the non-degenerate IVDs, TNF RI was seen in all degenerate IVDs (Figure 1). However, degenerate IVDs showed significantly less copy numbers for TNF RI than seen in non-degenerate IVDs (651 copies/100 ng cDNA in degenerate IVDs versus 1,087 copies/100 ng cDNA in non-degenerate IVDs; $P < 0.05$; Figure 1, Table 3).

Gene expression of IL-1 and TNF and their receptors in herniated human IVDs

IL-1 β gene expression was observed in a greater number of herniated IVDs (71%) than non-degenerate IVDs (63%). The level of gene expression was also higher in herniated IVDs than non-degenerate IVDs, although this did not achieve statistical significance ($P > 0.05$; Figure 1, Table 3). Similarly, TNF α was also seen in a greater proportion of herniated IVDs (71%) than non-degenerate IVDs (13%). TNF α was seen in

Figure 1



Absolute gene expression of IL-1 β , tumour necrosis factor (TNF) α and their receptors in human intervertebral discs (IVDs). The percentage of disc samples displaying gene expression for the target genes and the copy number/100 ng cDNA expressed within positive samples are given and data is represented as a box and whisker plot. (* = $P < 0.05$).

some herniated samples where IL-1 β was not expressed, although the majority of samples expressing TNF α also expressed IL-1 β . In addition, the level of TNF α gene expression was higher in herniated IVDs than that seen in non-degenerate and degenerate IVDs, although this did not achieve statistical significance (Figure 1, Table 3). No significant difference was seen between the level of gene expression for IL-1 β and TNF α in herniated IVDs (301 copies/100 ng cDNA for IL-1 β , and 520 copies/100 ng cDNA for TNF α ; Figure 1).

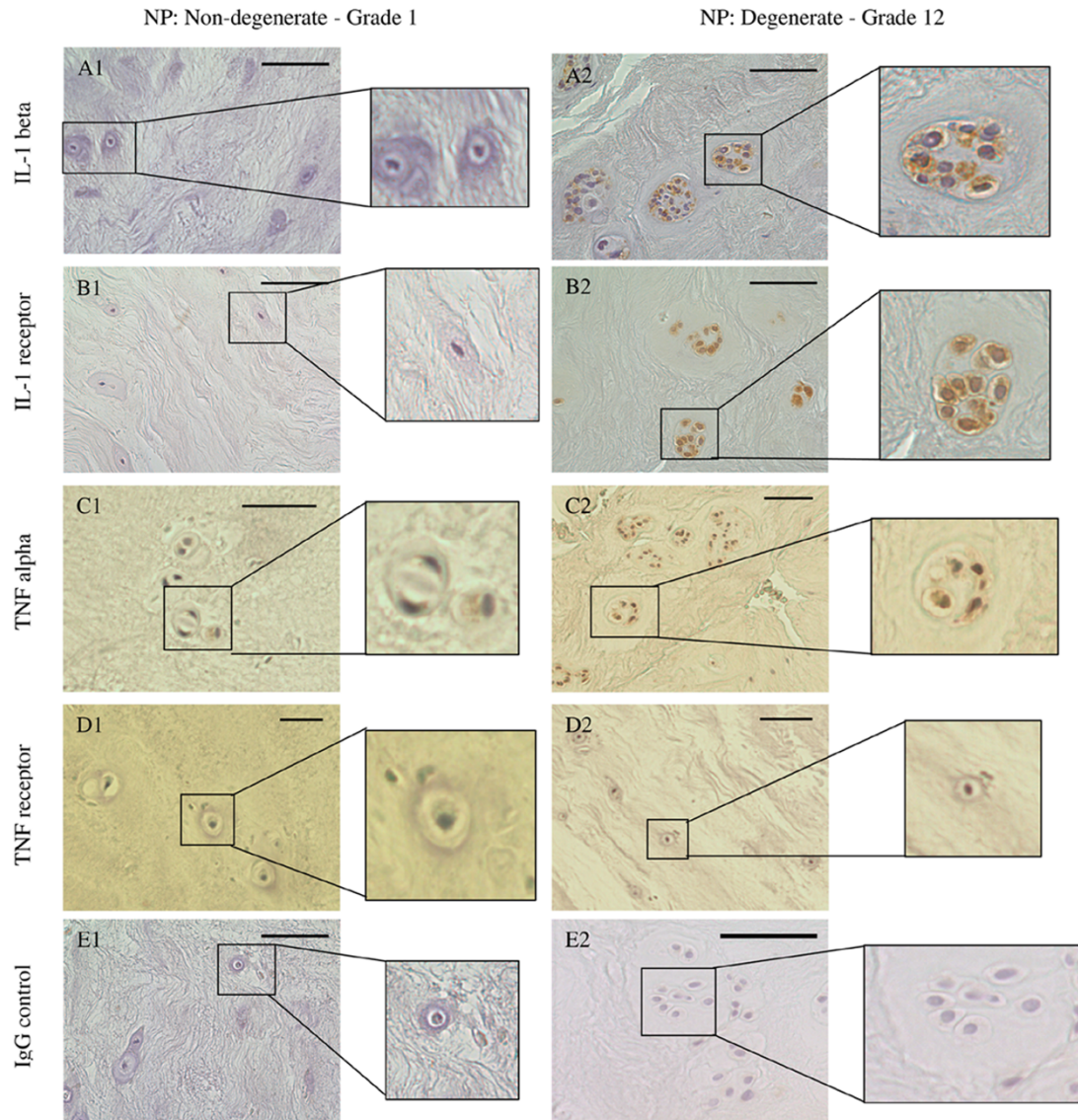
IL-1 RI was seen in a similar proportion of herniated and non-degenerate IVDs but in fewer IVDs than in degenerate IVDs. A non-significant increase in levels of IL-1 RI was also seen in herniated IVDs compared to non-degenerate IVDs but at lower levels than in degenerate IVDs (Figure 1, Table 3). Expression of TNF RI was seen in a lower proportion of herniated IVDs, with only 71% of samples displaying expression compared to all non-degenerate and degenerate IVDs. The level of TNF RI expression was also lower in herniated IVDs than in non-degenerate IVDs, although this did not reach statistical significance (Figure 1, Table 3).

Protein production and localisation of IL-1 and TNF and their receptors in human IVDs

Immunoreactivity for the four molecules (IL-1 β , TNF α , IL-1 RI and TNF RI) was observed in non-degenerate, degenerate and herniated IVDs. The immunostaining was generally restricted to the cytoplasm of native IVD cells (Figure 2). IgG controls were always negative (Figure 2). No immunopositivity was

observed in the matrix of the IVD or in blood vessels. Staining was particularly prominent in the cytoplasm of the chondrocyte-like cells of the NP and IAF, with significantly lower numbers of cells in the OAF showing immunopositivity for all four targets investigated ($P < 0.05$). IL-1 β and its receptor showed significantly more immunopositive cells in the NP than the IAF and the OAF ($P < 0.05$; Figure 3).

In non-degenerate IVDs, a similar proportion of IVD cells were immunopositive for IL-1 β and TNF α , with approximately 20% of cells in the NP and 10% in the IAF being immunopositive (Figure 3, Table 3). However, a greater proportion of cells (30% of cells in the NP and 20% of cells in the IAF) were immunopositive for IL-1 RI than TNF RI (10% of cells in the NP and 5% of cells in the IAF). The percentage of cells immunopositive for IL-1 β and TNF α was significantly increased in the NP and IAF of degenerate IVDs compared to non-degenerate IVDs ($P < 0.05$; Figure 3, Table 3). However, this increase was greater for IL-1 β than TNF α , with approximately 50% of cells in degenerate IVDs showing IL-1 β immunopositivity but only 30% TNF α immunopositive cells. The percentage of cells immunopositive for IL-1 RI was higher in degenerate than non-degenerate IVDs, although this only reached significance in the NP ($P < 0.05$; Figure 3, Table 3). However, no such increase was seen for TNF RI, where the number of immunopositive cells was low (3%); numbers of TNF RI immunopositive cells actually decreased in degenerate discs compared to non-degenerate discs, although this did not reach significance (Figure 3, Table 3).

Figure 2

Photomicrographs illustrating immunohistochemistry staining for IL-1 β , tumour necrosis factor (TNF) α and their receptors in human intervertebral discs. Results for non-degenerate discs (grade 1) are shown in A1 to E1 and result for degenerate discs (grade 12) are shown in A2 to E2: IL-1 β (A); IL-1RI (B); TNF α (C); TNF RI (D); IgG controls (E) were all negative. Immunopositivity shows as brown staining. Bars = 570 μ m.

When compared to non-degenerate IVDs, herniated IVDs also showed significantly higher numbers of cells immunopositive for IL-1 β , TNF α and IL-1 RI but not TNF RI (Figure 3, Table 3). The proportion of cells immunopositive for IL-1 β and IL-1 RI was similar in herniated and degenerate IVDs, but a greater proportion of TNF α immunopositive cells was seen in herniated than degenerate IVDs.

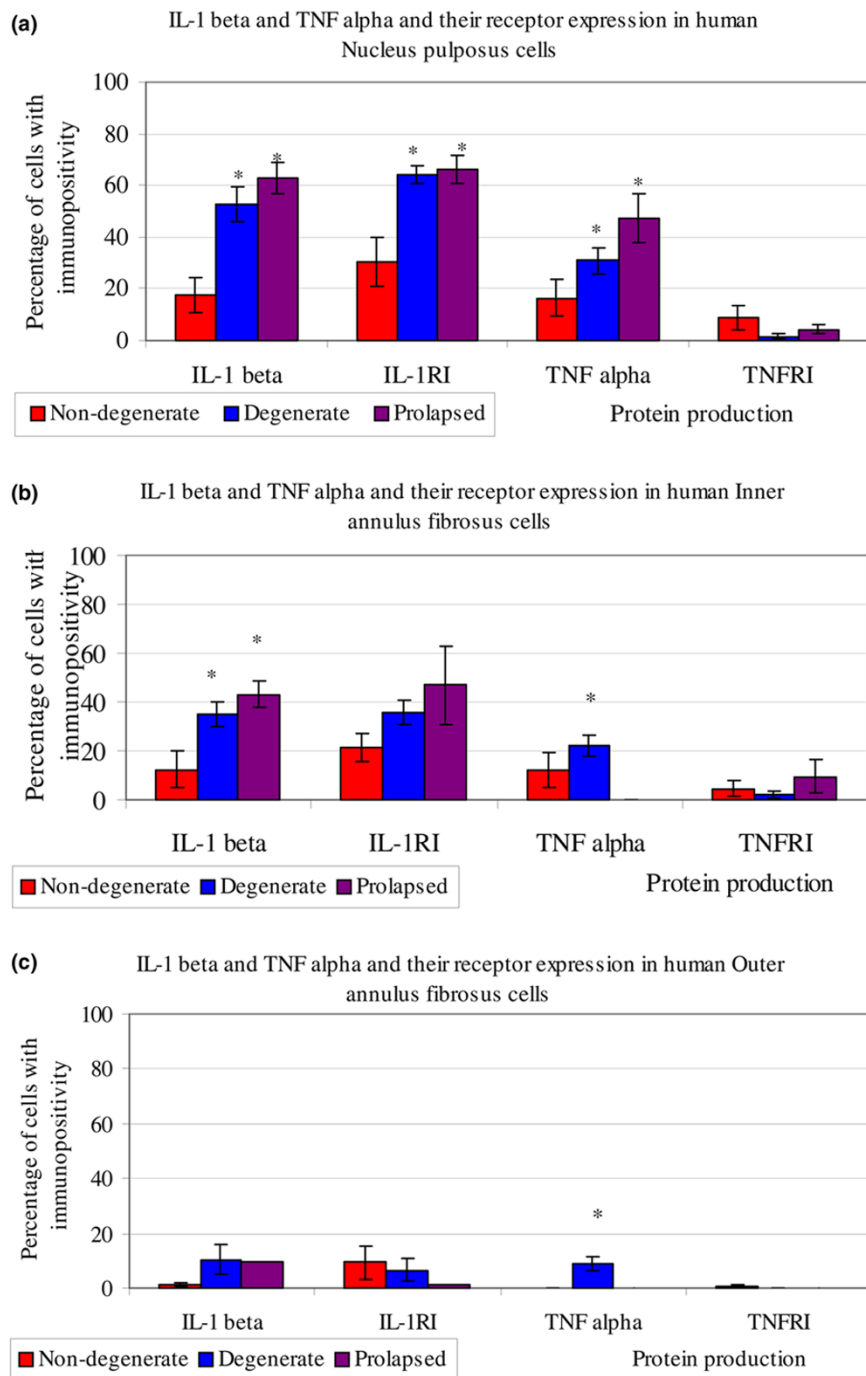
Discussion

The pathogenesis of IVD degeneration is still poorly understood, and a greater understanding is required prior to the development of successful therapeutic approaches to inhibit or delay IVD degeneration and herniation and thus treat LBP.

A number of cytokines have been implicated in the pathogenesis of IVD degeneration and herniation, with particular attention being paid to IL-1 and TNF α [11-20]. To our knowledge, this is the first study to simultaneously investigate the gene expression and protein production of IL-1 and TNF α and their receptors in non-degenerate, degenerate and herniated human IVDs.

This study demonstrated that IL-1 and TNF α are expressed along with their receptors in the human IVD. Both cytokines were present in non-degenerate IVDs at low levels, with similar numbers of immunopositive cells seen, although the gene expression analysis suggested that IL-1 β was more highly

Figure 3



Number of cells displaying immunopositivity for IL-1 β , tumour necrosis factor (TNF) α and their receptors in human human intervertebral discs. The percentage of cells with immunopositivity is given for IL-1 β , IL-1RI, TNF α and TNF RI in the (a) nucleus pulposus, (b) inner annulus fibrosus and (c) outer annulus fibrosus of non-degenerate, degenerate and herniated discs ($n = 39$). Data are presented as means \pm 2 standard error (as a representative of 95% confidence interval). * $P < 0.05$.

expressed than TNF α in non-degenerate IVDs. TNF RI gene expression was observed in all non-degenerate samples; however, immunohistochemistry showed only a small number of cells with TNF RI protein, suggesting that the gene was not

translated to protein. An alternative explanation may be that real time PCR is more sensitive than immunohistochemistry and, thus, may have identified gene expression where protein levels could not be detected. IL-1 RI protein, however, was

produced by a greater number of cells than TNF RI, suggesting that non-degenerate IVD cells were more responsive to the local levels of IL-1 than TNF α . This suggests that IL-1 is important in the normal homeostasis of the IVD where IL-1 is controlled by the natural antagonist IL-1Ra, which we have previously shown to be synthesized by endogenous IVD cells [12].

During IVD degeneration and IVD herniation, an increase in the protein production for both cytokines was observed, agreeing with the two earlier studies on protein production of these cytokines in degenerate human IVDs [12,21]. However, the number of IL-1 β immunopositive cells was higher than the number of TNF α immunopositive cells in both degenerate and herniated samples. In addition, gene expression for IL-1 β but not TNF α was significantly increased in degenerate compared to non-degenerate IVDs.

This study also showed an increase in both IL-1RI gene expression and protein production in degenerate and herniated IVDs compared to non-degenerate IVDs, a finding that agrees with our earlier study in which we demonstrated increased immunopositivity for IL-1RI in degenerate compared to non-degenerate IVDs [12].

The biological activity of TNF is mediated through two distinct but structurally homologous TNF receptors, type I (p60 or p55) and type II (p80 or p75). Although TNF binds to each with high affinity, TNF RI is more ubiquitously expressed and it is generally believed that TNF RI is responsible for the majority of biological actions of TNF while TNF RII may function to potentiate the effects of TNF RI. We have previously shown that TNF RII is not expressed by IVD cells either in normal or degenerate IVDs [24]. The current study also shows the expression and production of TNF RI within human intervertebral IVDs, which together with the recent study by Bachmeier and colleagues [22] suggests that human IVD cells are capable of responding to TNF α *in vivo*. However, no increase in TNF RI synthesis was seen during IVD degeneration or herniation. In fact, a decrease in TNF RI gene and protein expression was seen in degenerate and herniated IVDs compared to non-degenerate IVDs, suggesting that the biological activity of TNF α is reduced during degeneration and herniation due to these IVDs having reduced responsiveness to TNF α .

We have previously demonstrated that in human IVD cells, IL-1 treatment results in decreased matrix production and increased production of the degradation enzymes (matrix metalloproteinases and ADAMTs (a disintegrin and metalloprotease with thrombospondin motifs)) [12], features characteristic of IVD degeneration [5,7]. Similar responses have been observed in animal IVD cells following treatment with TNF α [25], although these responses have not been shown to date in human IVDs. Here we demonstrate the expression and localisation of the TNF RI to the chondrocyte-like cells of the human intervertebral IVDs, and although only

expressed in a low percentage of IVD cells, this suggests that the human IVDs are capable of responding to TNF α , which could result in decreased matrix synthesis and increased matrix degradation in a similar manner to that seen with IL-1. However, as our data demonstrated low expression of TNF RI in human IVD samples, this suggests that these effects would be limited.

Although our study indicates that TNF α may have limited effects on IVD cells during IVD degeneration, during IVD herniation the TNF α produced by IVD cells in the herniated IVDs may have additional detrimental effects. During IVD herniation, IVD tissue comes into contact with the nerve root and inflammatory cells. TNF α has been shown to result in the sensitisation of nerve roots and stimulation of nerve growth factor [15,26,27]. As such, the TNF α generated by the IVD cells in herniated IVD tissue could have a detrimental effect on the local nerves, resulting in the generation of LBP. Indeed, the use of TNF blocking antibodies has shown some promise in a small clinical trial [28,29], although two more recent placebo controlled trials suggest that this treatment may only be of use in a small subset of sciatica patients (that is, those with L4/5 or L3/4 herniation with modic changes) [30,31].

Our data suggest that TNF α , in addition to IL-1, may have a role in the pathogenesis of IVD degeneration. However, we have shown that IL-1 is expressed and produced at higher levels than TNF α , suggesting IL-1 may be more predominant in the processes of IVD degeneration. In addition, this study has highlighted that IL-1 RI expression by native IVD cells is upregulated during IVD degeneration and herniation, suggesting that there is increased responsiveness to IL-1 during these disease states. In contrast, TNF RI was only produced by a small proportion of IVD cells in non-degenerate IVDs and its expression and production were decreased during IVD degeneration and herniation, suggesting that the responsiveness of IVD cells to TNF α in degenerate human IVDs may only be at low levels.

The data presented in the current study together with our previous findings [12] suggest that IL-1 would be a viable target for the inhibition of disc degeneration. Indeed, IL-1Ra therapies such as Anakinra are already in clinical use for limiting cartilage degradation in rheumatoid arthritis and osteoarthritis and, as such, its pharmacology and side effects are increasingly well understood [32]. We have previously demonstrated successful transfer of IL-1Ra to IVD tissue *in vitro* using gene therapy and, thus, delivery to the IVD is a viable option [33]. The inhibition of IL-1 driven processes, leading to disc degeneration, could be important in two therapeutic strategies; first, inhibition of disc degeneration at an early stage (such as degeneration induced at adjacent levels following spinal fusion or disc replacement); and second, defining the optimal tissue niche for regenerating the end stage degenerate IVD.

Conclusion

Our data show that both IL-1 and its receptor are significantly upregulated in IVD degeneration and are, therefore, more likely to be major mediators in the processes of IVD degeneration. By contrast, whilst TNF α expression is upregulated in degeneration, gene and protein expression of the predominant TNF receptor (TNF R1) is, if anything, reduced, with few cells showing demonstrable protein production. The implication, therefore, is that overall biological activity of TNF α within the degenerate IVD is reduced. The herniated IVD is, however, rather different. Although TNF R1 expression is low, TNF α gene and protein expression are higher overall than in the non-degenerate IVD and whilst the biological activity of TNF α within the IVD tissue will still be restricted by the low receptor expression our results would support the data from others implicating a potential paracrine effect of TNF produced by IVD cells in inducing sciatica. To conclude, the results from this study suggest that IL-1 rather than TNF α would be a better target for therapeutic approaches to inhibit IVD degeneration and associated LBP.

Competing interests

The authors declare that they have no competing interests.

Authors' contributions

CLM helped conceive the study, participated in its design, performed all the laboratory work and analysis and drafted the manuscript. AJF helped to secure funding, participated in interpretation of data and contributed to the preparation of the final manuscript. JAH conceived the study, secured funding, contributed to its design and co-ordination, and participated in interpretation of data and co-wrote the manuscript. All authors read and approved the final manuscript.

Acknowledgements

This work was funded by a BackCare grant and was undertaken in the Human Tissue Profiling Laboratories of the Tissue Injury and Repair research group that receive core support from the ARC (ICAC grant F0551) and MRC (Co-operative Group Grant G9900933) and the joint Research Councils (MRC, BBSRC, EPSRC) UK Centre for Tissue Engineering (34/TIE 13617).

References

- Luoma K, Riihimaki H, Luukkonen R, Raininko R, Viikari-Juntura E, Lamminen A: **Low back pain in relation to lumbar disc degeneration.** *Spine* 2000, **25**:487-492.
- Maniadakis N, Gray A: **The economic burden of back pain in the UK.** *Pain* 2000, **84**:95-103.
- Krismer M, van Tulder M: **Low back pain (non-specific).** *Best Pract Res Clin Rheumatol* 2007, **21**:77-91.
- Weiler C, Nerlich A, Zipperer J, Bachmeier BE, Boos N: **2002 SSE Award Competition in Basic Science: Expression of major matrix metalloproteinases is associated with intervertebral disc degradation and resorption.** *Eur Spine J* 2002, **11**:308-320.
- Le Maitre CL, Freemont AJ, Hoyland JA: **Localization of degradative enzymes and their inhibitors in the degenerate human intervertebral disc.** *J Pathol* 2004, **204**:47-54.
- Sive JJ, Baird P, Jeziorski M, Watkins A, Hoyland JA, Freemont AJ: **Expression of chondrocyte markers by cells of normal and degenerate intervertebral discs.** *Mol Pathol* 2002, **55**:91-97.
- Le Maitre CL, Freemont A, Hoyland J: **Human disc degeneration is associated with increased MMP 7 expression.** *Biotech Histochem* 2006, **81**:125-131.
- Ahn SH, Cho YW, Ahn MW, Jang SH, Sohn YK, Kim HS: **mRNA expression of cytokines and chemokines in herniated lumbar intervertebral discs.** *Spine* 2002, **27**:911-917.
- Kang JD, Georgescu HI, McIntyre-Larkin L, Stefanovic-Racic M, Evans CH: **Herniated cervical intervertebral discs spontaneously produce matrix metalloproteinases, nitric oxide, interleukin-6, and prostaglandin E2.** *Spine* 1995, **20**:2373-2378.
- Kang JD, Georgescu HI, McIntyre-Larkin L, Stefanovic-Racic M, Donaldson WF III, Evans CH: **Herniated lumbar intervertebral discs spontaneously produce matrix metalloproteinases, nitric oxide, interleukin-6, and prostaglandin E2.** *Spine* 1996, **21**:271-277.
- Le Maitre CL, Richardson SMA, Williamson B, Ross R, Freemont AJ, Hoyland JA: **IL-1: role in degeneration of the intervertebral disc and its inhibition using IL-1Ra gene transfer.** *Mol Therapy* 2003, **5**:S405.
- Le Maitre CL, Freemont AJ, Hoyland JA: **The role of interleukin-1 in the pathogenesis of human intervertebral disc degeneration.** *Arthritis Res Ther* 2005, **7**:R732-R745.
- Doita M, Kanatani T, Harada T, Mizuno K: **Immunohistologic study of the ruptured intervertebral disc of the lumbar spine.** *Spine* 1996, **21**:235-241.
- Takahashi H, Suguro T, Okazima Y, Motegi M, Okada Y, Kakiuchi T: **Inflammatory cytokines in the herniated disc of the lumbar spine.** *Spine* 1996, **21**:218-224.
- Igarashi T, Kikuchi S, Shubayev V, Myers RR: **2000 Volvo Award winner in basic science studies: Exogenous tumor necrosis factor-alpha mimics nucleus pulposus-induced neuropathology. Molecular, histologic, and behavioral comparisons in rats.** *Spine* 2000, **25**:2975-2980.
- Olmarker K, Larsson K: **Tumor necrosis factor alpha and nucleus-pulposus-induced nerve root injury.** *Spine* 1998, **23**:2538-2544.
- Murata Y, Onda A, Rydevik B, Takahashi K, Olmarker K: **Selective inhibition of tumor necrosis factor-alpha prevents nucleus pulposus-induced histologic changes in the dorsal root ganglion.** *Spine* 2004, **29**:2477-2484.
- Larsson K, Rydevik B, Olmarker K: **Disc related cytokines inhibit axonal outgrowth from dorsal root ganglion cells in vitro.** *Spine* 2005, **30**:621-624.
- Murata Y, Onda A, Rydevik B, Takahashi I, Takahashi K, Olmarker K: **Changes in pain behavior and histologic changes caused by application of tumor necrosis factor-alpha to the dorsal root ganglion in rats.** *Spine* 2006, **31**:530-535.
- Cooper RG, Freemont AJ: **TNF-alpha blockade for herniated intervertebral disc-induced sciatica: a way forward at last?** *Rheumatology (Oxford)* 2003, **43**(2):119-21.
- Weiler C, Nerlich AG, Bachmeier BE, Boos N: **Expression and distribution of tumor necrosis factor alpha in human lumbar intervertebral discs: a study in surgical specimen and autopsy controls.** *Spine* 2005, **30**:44-53.
- Bachmeier BE, Nerlich AG, Weiler C, Paesold G, Jochum M, Boos N: **Analysis of tissue distribution of TNF-alpha, TNF-alpha-receptors, and the activating TNF-alpha-converting enzyme suggests activation of the TNF-alpha system in the aging intervertebral disc.** *Ann NY Acad Sci* 2007, **1096**:44-54.
- Le Maitre CL, Freemont AJ, Hoyland JA: **Accelerated cellular senescence in degenerate intervertebral discs: A possible role in the pathogenesis of intervertebral disc degeneration.** *Arthritis Res Ther* 2007, **9**:R45.
- Freemont AJ, Watkins A, Le Maitre C, Baird P, Jeziorska M, Knight MT, Ross ER, O'Brian JP, Hoyland JA: **Nerve growth factor expression and innervation of the painful intervertebral disc.** *J Pathol* 2002, **197**:286-292.
- Seguin CA, Pilliar RM, Roughley PJ, Kandel RA: **Tumor necrosis factor-alpha modulates matrix production and catabolism in nucleus pulposus tissue.** *Spine* 2005, **30**:1940-1948.
- Abe Y, Akeda K, An HS, Aoki Y, Pichika R, Muehleman C, Kimura T, Masuda K: **Proinflammatory cytokines stimulate the expression of nerve growth factor by human intervertebral disc cells.** *Spine* 2007, **32**:635-642.
- Mulleman D, Mammou S, Griffoul I, Watier H, Goupille P: **Pathophysiology of disk-related sciatica. I. - Evidence supporting a chemical component.** *Joint Bone Spine* 2006, **73**:151-158.

28. Tobinick E, Britschgi-Davoodifar S: **Perispinal TNF-alpha inhibition for discogenic pain.** *Swiss Med Wkly* 2003, **133**:170-177.
29. Karppinen J, Korhonen T, Malmivaara A: **Infliximab, used to manage severe sciatica.** *Spine* 2003, **28**:750-754.
30. Korhonen T, Karppinen J, Paimela L, Malmivaara A, Lindgren KA, Bowman C, *et al.*: **The treatment of disc-herniation-induced sciatica with infliximab: one-year follow-up results of FIRST II, a randomized controlled trial.** *Spine* 2006, **31**:2759-2766.
31. Cohen SP, Wenzell D, Hurley RW, Kurihara C, Buckenmaier CC III, Griffith S, *et al.*: **A double-blind, placebo-controlled, dose-response pilot study evaluating intradiscal etanercept in patients with chronic discogenic low back pain or lumbosacral radiculopathy.** *Anesthesiology* 2007, **107**:99-105.
32. Kary S, Burmester GR: **Anakinra: the first interleukin-1 inhibitor in the treatment of rheumatoid arthritis.** *Int J Clin Pract* 2003, **57**:231-234.
33. Le Maitre CL, Freemont AJ, Hoyland JA: **A preliminary *in vitro* study into the use of IL-1Ra gene therapy for the inhibition of intervertebral disc degeneration.** *Int J Exp Pathol* 2006, **87**:17-28.